

## **CORTICOTOMY- ASSISTED ORTHODONTIC TREATMENT (Case report)**

Sofijanka Gerasimova Pisevska, Ljuba Simjanovska\*, Mirjana Markovska Arsovska, Marija Peeva Petreska\*,

University Dental Clinical Center "St. Panteleimon" Skopje

\*Faculty of Dentistry, Ss.Cyril and Methodius University, Skopje

### **Abstract**

Ankylosis of tooth is defined as the fusion of mineralized root surface of the surrounding alveolar bone with the obliteration of the periodontal ligament. Tooth ankylosis can occur at any time during the eruption, and diagnosis can be made by clinical and radiographic evaluation. Conventional orthodontic treatment is insufficient for ankylosis tooth movement and requires special treatment approaches. Corticotomy is a surgical technique which uses osteotomy of the bone for reposition of the ankylosed tooth and adjacent alveolar bone.

This paper presents leveling of an impacted and ankylosed upper canine done with corticotomy-assisted treatment.

We present a case of a 12-year-old girl with symmetric face, normal growth development for her age and maintained good oral hygiene and systemic health. The treatment included bimaxillary correction and correction of the dental relationship. Corticotomy-assisted orthodontic treatment was planned for upper right canine tooth, because we assumed that conventional orthodontic treatment might not be successful.

Corticotomy-facilitated orthodontics is an effective treatment alternative in adults with severe malocclusion to decrease the treatment time and increase the quality of treatment. The corticotomy cuts and perforation has to be done on cortical bone layer and extend only into the superficial aspect of the medullary bone. Corticotomies can be a powerful and save tool to improve the quality and duration of orthodontic treatment.

**Key words:** ankylosis, canine, corticotomy

### **Introduction**

Ankylosis of tooth is defined as the fusion of mineralized root surface of the surrounding alveolar bone with obliteration of the periodontal ligament. Tooth ankylosis can occur at any time during eruption and diagnosis can be made by clinical and radiographic evaluation.

One of the dental fields that has made a great progress in the modern era is orthodontics, which helped in reducing the treatments as much as possible and in avoiding the incidence of adverse effects such as root resorption, oral hygiene difficulties or appearance of caries [1,2]. Various methods have been introduced to accelerate tooth movement with orthodontic force to evoke the biological action and response of the alveolar bone. Conventional orthodontic treatment is insufficient for ankylosis tooth movement and requires special treatment approaches.

There are new techniques combined with the orthodontic treatment to accelerate tooth movement and they can be divided into surgical and non-surgical procedures. The surgical method includes corticotomy, one of the representative methods for accelerating tooth movement through invasive surgical treatment, with different design and modification.

The development of corticotomy-assisted orthodontic treatment is a promising source for movement of the ankylosed tooth. Corticotomy is a surgical technique which uses osteotomy of the bone for reposition of both the ankylosed tooth and the adjacent alveolar bone. The cortex of the bone is cut, perforated or mechanically altered [3]. Orthodontic appliances are used to move the tooth over the period of few weeks following surgery. Corticotomy intentionally inflicts mechanical damage on the cortical bone. This increases bone remodeling to accelerate the repair and achieve functional recovery. The process takes place through recruiting osteoblasts and osteoclast activated by local intercellular mediators [4,5,6]. This creates a transitory state of osteoporosis, characterized by a reduction in bone density, which causes less resistance of tooth movement [4,7]. The principle of

alveolar corticotomy is based on a biological concept-regional acceleratory phenomenon (RAP), described for the first time by Frost [8]. This post-operative osteopenia is transient and reversible and physiological bone healing will allow the gradual restoration of bone density.

Wilcko and brothers introduced accelerated osteogenic orthodontics tooth movement (AOOTM) as a method to accelerate tooth movement by selective decortications of the labial and lingual cortex [9,10]. Demineralization/remineralization of bone occurred ideally in younger adolescents during tooth movement. In adult remineralization did not occur sufficiently, so bone grafting was performed where the tooth would move to provide alveolar housing during tooth movement [11,10,12].

Burgami *et al.* extended the scope of conventional orthodontic treatment by corticotomy in combination with bone grafting, overcoming the limitations of traditional orthodontic treatment [13].

Maxillary canines have dentofacial esthetic and functional importance and are second in frequency of impaction. Canine retraction, which is a relatively slow process, could considerably lengthen this treatment period, particularly in adults where the tissue response to orthodontic application is much slower than in children and adolescents.

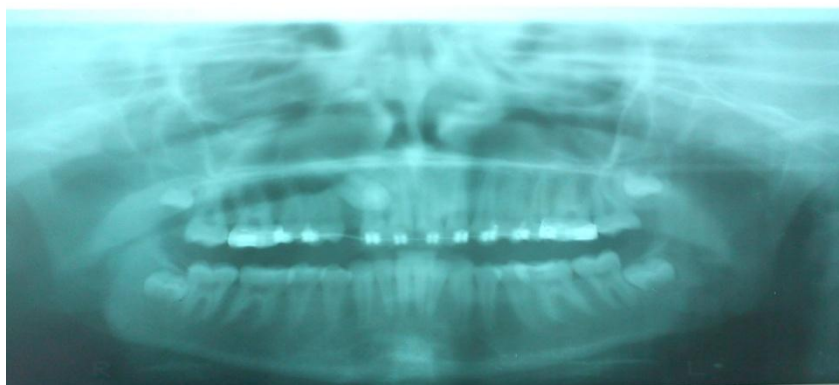This paper presents leveling of an impacted and ankylosed upper canine done with corticotomy-assisted orthodontic treatment.

### **A case report**

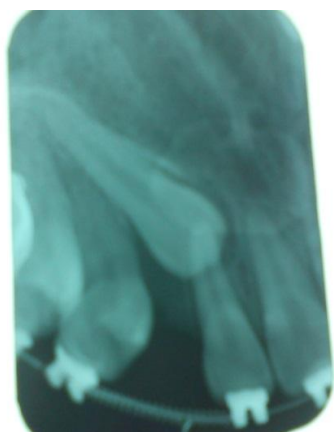The patient was a 12-year old girl with symmetric face, normal growth development for her age and maintained a good oral hygiene and systemic health. There was no record related to systematic alterations that were diagnosed in this patient. The treatment included bimaxillary correction and correction of the dental relationship. A panoramic radiograph and retroalveolar X-ray revealed presence of angled alignment and orientation for eruption of the right canine, and needed space [Picture 1 and 2]. Intraoral examination revealed presence of all permanent teeth with the absence of the upper right canine [Picture 3].

Corticotomy-assisted orthodontic treatment was planned for upper right canine tooth, because we assumed it would never move with orthodontic treatment. All aseptic preparations of the operative field were made. Corticotomy was performed under local anesthesia (Scandonest 2%) by using mucoperiosteal flap from mesial to distal surface of upper canine [Picture 4].

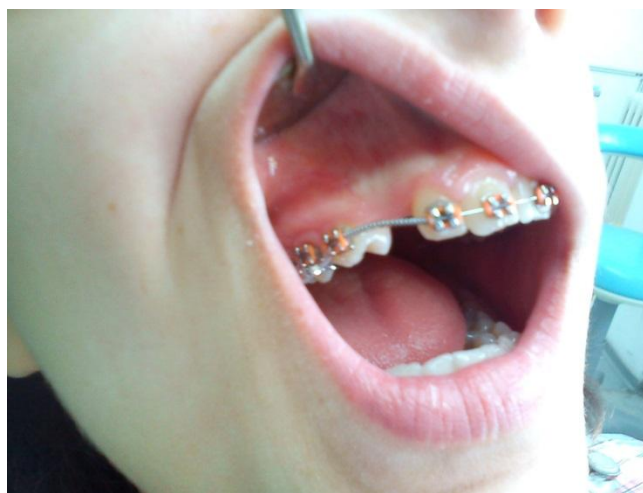
After pulling up the mucoperiosteal flap, the position of the canine was palatal. Corticotomy was performed by using a drill number 5 and was made deep in the cortical bone and extended to spongiosa. The mucoperiosteal flap was sutured with non-resorbable silk sutures, taking care to preserve the interdental papilla. The excision around the tooth was made and protective barrier was placed. The regular check-ups were made on days 2, 7 and 10 after surgery. The sutures were removed after 10 days.



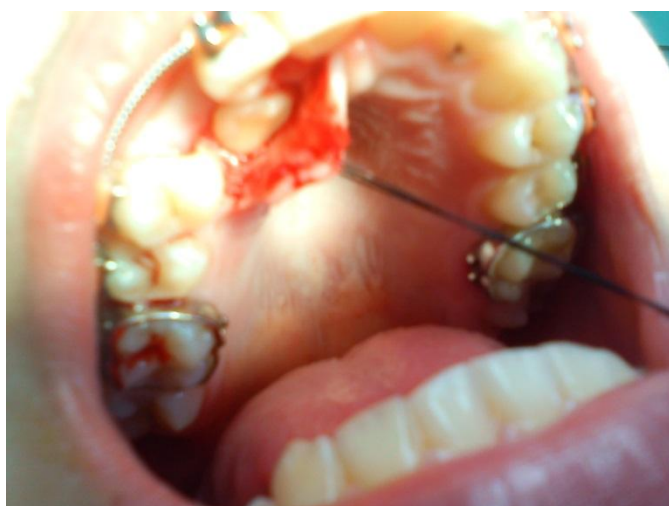**Picture 1.** X-rays, Panoramix



**Picture 2.** Retroalveolar X-ray



**Picture 3.** Intraoral status



**Picture 4.** Mucoperiosteal flap

### **Discussion**

Tooth ankylosis is reported as a complication in orthodontic practice. Several procedures are introduced to treat ankylosed tooth with successful result such as osteotomies, corticotomies and distraction osteogenesis [14-17]. Distraction osteogenesis is a technique for new bone formation without bone grafting. Osteotomy is the other treatment option by repositioning of the ankylosed tooth with surrounding alveolar bone. Alveolar corticotomies have been used multidisciplinary along with orthodontic treatment. Corticotomy technique is defined as any intentional surgical injury to cortical bone which can produce mobilization of the tooth with adjacent bones and soft tissue [18]. A deliberate surgical injury to the cortical bone in order to reduce its resistance to tooth movement is referred to as corticotomy. Corticotomy has been proposed as an alternative to conventional orthodontic treatment in difficult adult cases for rapid tooth movement. It is surgical intervention

limited to cortical bone that has been suggested as an alternative to facilitate the treatment of complex occlusal problems. The corticotomy technique has been modified to eliminate the possible risk, such as periodontal damage, devitalization of the teeth and osseous segment because of inadequate blood supply. The explanation for canine retraction after alveolar corticotomy is “RAP”, which reduces bone density and resistance of the alveolar cortical bone to help the orthodontic movement of the tooth [19]. Corticotomy is making the healing process 2-10 times faster compared to conventional orthodontic treatment.

Wilcko and Wilcko believe that increase in the rate of the tooth movement is due primarily to the demineralization process that occurs in the cancellous bone surrounding the tooth socket and secondarily to alterations within the periodontal ligament [11].

Frost noticed that the greatest resistance to tooth movement was due to cortical walls [20]. Breaking them up would reduce the treatment time. Fisher [21] considered that corticotomy encourages faster tooth movement because it reduces the bone walls.

Bhattacharya *et al.* agreed with those papers in which the tooth moved twice as fast when corticotomy had been performed [5].

In the studies by Al-Naoum *et al.* and Cassatta *et al.* who had used more invasive surgical procedures a significant increase in postoperative pain was found [22,23].

The most promising studies with better postoperative conditions are those in which the procedure is simpler and does not involve flaps [24].

Leethanakul *et al.* concluded that the only significant factor correlated with canine movement was the quantity of bone remaining in the mesial wall of the socket. These authors concluded that one factor such as the root anatomy of the canine had an influence on the movement. Chung *et al.* reported that the complete retraction of anterior teeth combined with corticotomy in a case with severe bimaxillary protrusion took less than 3 1/2 months [25].

Geramc observed the total dramatical reduction in the orthodontic treatment (16 months) when compared to the average treatment time for extraction therapy (31 month) [26,27,28]. In corticotomy-facilitated orthodontics, the reduction of orthodontic treatment time by approximately 50% was observed [29].

Corticotomy may lead to gingival recession. No periodontal damage or loss of the tooth vitality was reported. Only one study reported dentin hypersensitivity in one patient who recovered without complications after 5 weeks [30].

There was one case of severe pain and swelling in the first 7 postoperative days as well as subcutaneous hematomas of the face and neck [29].

Overcompression of periodontal ligament can lead to hyalinization necrosis, the removal of which can be associated with root resorption.

There have been several reports of interdental bone loss and decrease of attached gingivae and periodontal defects observed in some cases with short interdental distance [31].

In comparison with traditional orthodontics, the fact that the teeth can be moved more rapidly with corticotomy techniques, thus resulting in shortened treatment times, is advantageous to the patient's periodontal health because less time in fixed appliances reduces the time available for relatively benign commensal bacterial biofilms to assume qualitative changes and convert to a destructive cytotoxic potential often seen when fixed appliances have remained on the teeth for more than 2-3 years [11].

For the better flow supply corticotomy can be performed by one stage technique also known as a blind technique or by using piezoelectric surgical device that can reduce soft tissue in the same time [32,33,34].

Corticotomy in combination with guided bone regeneration has the potential to increase the scope of conventional orthodontic treatment by allowing for expansive movements beyond the traditional limits [35].

Verna *et al.* suggest that the moment-to-force ratios used in conventional orthodontic should be modified in case of techniques that decrease bone density to enhance tooth movement rate [36].

## **Conclusion**

Corticotomy-facilitated orthodontics is an effective treatment alternative in adults with severe malocclusion to decrease the treatment time and increase the quality of treatment. Corticotomy cut and perforation has to be done on cortical bone layer and extend only into the superficial aspect of the medullary bone. Corticotomies can be a powerful and save tool to improve the quality and duration of orthodontic treatment.

## **References**

1. Gkantidis N, Mistakidis I, Kouskoura T, Pandis N. Effectiveness of non-conventional methods for accelerated orthodontic tooth movement: A systematic review and metaanalysis. *J Dent.* 2014;42:1300-19
2. Shoreibah EA, Samir A, Ibrahim A, Attia MS, Diab MMN. Clinical and radiographic evaluation of bone grafting in corticotomy-facilitated orthodontic in adults. *J Int Acad Periodontol.*2012;14:105-13
3. Murphy KG, Wilcko MT, Wilcko WM, Ferguson DJ. Periodontal accelerated osteogenic orthodontics: bone grafting with periosteum. *J Oral maxillofac Surg* 67:2160e2166,2009
4. Aboul-Ela SM, El-Beialy AR, El-Saysed KM, Selim EM, El-Mangoury NH, Mostafa YA. Miniscrew implant-supported maxillary canine retraction with and without corticotomy-facilitated orthodontics. *Am J of Orthod Dentofacial Orthop.*2011;139:252-9
5. Bhattacharya P, Bhattacharya H, Anjum A, Bhandari R, Agarwal DK, Gupta A. Assessment of Corticotomy Facilitated Tooth Movement and Changes in Alveolar Bone Thickness-A CT Scan Study. *J Clin Diagn Res.*2014;8:ZC26-30
6. Frost HM. The regional acceleratory phenomenon: a review. *Henry Ford Hosp Med J* 1983;31:3-9
7. Hassan AH, Ahmad A, Fraidi A, Samar H. Corticotomy-assisted orthodontic treatment: Review. *Open Dent J.*2010;13:159-64
8. Frost Hm. The biology of fracture healing. An overview for clinicians. Part I. *Clin Orthop relat Res* 1989:283-93
9. Wilcko WM, Wilcko T, Bouquot JE, Ferguson DJ. Rapid orthodontics with alveolar reshaping: two case reports of decrowding. *Int J Periodontics Restorative Dent.*2001;21:9-19
10. Wilcko MT, Wilcko WM, Pulver JJ, Bissada NF, Bouquot JE. Accelerated osteogenic orthodontics technique: a 1-stage surgically facilitated rapid orthodontic technique with alveolar augmentation. *J Oral Maxillofac Surg.*2009;67:2149-2159
11. Wilcko MT, Wilcko WM, Bissada NF. An evidence-based analysis of periodontally accelerated orthodontic and osteogenic techniques: a synthesis of scientific perspectives. *Semin Ortod.*2008;14:305-316
12. Wilcko WM, Ferguson DJ, Bouquot JE, Wilcko MT. Rapid orthodontic decrowding with alveolar augmentation: case report. *World J Orthod.*2003;4:197-205
13. Brugnamì F, Caiazzo A, Mehra P. Can corticotomy (with or without bone grafting) expend the limits of safe orthodontic therapy? *J Oral Biol Craniofac Res.*2018;8:1-6
14. Kurol J, Thilander B. Infraocclusion of primary molars and the effects on occlusal development, a longitudinal study. *Eur J Orthod* 1984 Nov;6(4):277-93

15. Ohkubo K, Susami T, Mori Y, et al. Treatment of ankylosed maxillary central incisors by singletooth dento-osseous osteotomy and alveolar bone – distraction. *Oral Surg Oral Med Oral Pathol Oral Radiol Endod* 2011 May;111(5):561-7
16. Aludden H, Jensen T. Treatment of an ankylosed central incisor by single tooth dento-osseous osteotomy and a simple distraction devise. *Open J Stomatology* 2016;6(4):97-102
17. Kofod T, Wurtz V, Melsen B. Treatment of an ankylosed central incisor by single tooth dentoosseous osteotomy and simple distraction devise. *Am J Orthod Dentofacial Orthop* 2005;127(1):72-80
18. Uzuner FD, Darendeliler N. Dentoalveolar surgery techniques combined with orthodontic treatment: A literature review. *Eur J Dent* 2013 Apr;7(2):257-65
19. Frost HM. The regional acceleratory phenomenon. *Ortop Clin North Am* 1981;725-6
20. Frost HM. The regional acceleratory phenomenon: a review. *Henry Ford Hosp Med J*.1983;31;3-9
21. Fischer TJ. Orthodontic treatment acceleration with corticotomy-assisted exposure of palatally impacted canines. *Angle Orthod*.2007;77:417-20
22. Al-Naoum F, Hajeer MY, Al-Jundi A. Does alveolar corticotomy accelerate orthodontic tooth movement when retracting upper canines? A split-mouth desing randomized controlled trial. *J Oral Maxillofac Surg*.2014;72:1880-9
23. Cassetta M, Di Carlo S, Giansanti M, Pompa V, Pompa G, Barbato E. The impact of osteotomy technique for corticotomy-assisted orthodontic treatment (CAOT) on oral health-related quality of life. *Eur Rev for Med Pharmacol Sci*.2012;16:1735-40
24. Leethanakul C, Kanokkulchai S, Pongpanich S, Leepong N, Charoemratrote C. Interseptal bone reduction on the rate of maxillary canine retraction. *angle Ortod*. 2014;84:839-45
25. Chung KR, Oh MY, Ko SJ. Corticotomy assisted orthodontics. *J Clin Orthod*.2001;35:331-9
26. Germec D, Giary B, Kocadereli I, Enacar A. Lower Incisor Retraction with a Modified Corticotomy: *Angle Orthod*.2006.76:882-90
27. Vig PS, Weintraub JA, Brown C, Kowalski CJ. The duration of orthodontic treatment for patient with or without extraction. *Am J Orthod Dentofacial Orthop*.1990;97:45-51
28. Kocadereli I. Changes in soft tissue profile after orthodontic treatment with and without extractions. *Am J Orthod Dentofacial Orthop*.2002;122:67-72
29. Gantes B, Rathbun E, Anholm M. Effects on the periodontium following corticotomy-facilitated orthodontics: Case reports. *J Periodontol*.1990;61:234-8
30. Hernandez-Alfaro F, Guijarro-Martinez R: Endoscopically assisted tunnel approach for minimally invasive corticotomies: a preliminary report. *J periodontal* 83:574e580,2012
31. Kwon HJ, Pihlstom B, Waite DE. Effects on the periodontium of vertical bone cutting for segmental osteotomy. *J Oral Maxillofac Surg*.1985;43:952-
32. Won Lee. Corticotomy for orthodontic tooth movement. *J Korean Assoc Oral Maxillofac Surg*.2018;44(6);251-258.
33. Alfawal AMH, Hajeer MY, Ajaj MA, Hamadah O, Brad B. Evaluation of piezocision and laser-assisted flapless corticotomy in the acceleration of canine retraction: a randomized controlled trial. *Head Face Med*.2018;14:4
34. Viwattanatipa N, Charnchairerk S. The effectiveness of corticotomy and piezocision on canine retraction a systematic review: *Korean J Orthod*. 2018;48:200-211
35. Brugnami F, Caiazzo A, Nehra P. Can corticotomy (with or without bone grafting) expand the limits of safe orthodontic therapy? *J Oral Biol Craniofac Res*.2018;8(1):1-6.

36. Verna C, Cattaneo PM, Dalstra M. Corticotomy affects both the modus and magnitude of orthodontic tooth movement. *Eur J Orthod.*2018;40(1):107-112