

ANATOMICAL VARIATIONS OF THE AORTIC ARCH

Zhivadnikov Julija¹, Matveeva N¹, Zafirova B¹, Dodevski A¹, Petrovska T²

¹ Institute of Anatomy, Medical Faculty, Skopje, R. Macedonia

² PHI University Clinic for Surgical Diseases St. Naum Ohridski-Skopje

Abstract

Anatomical variations of the aortic arch and its branches can have important implications on prognosis and management of surgical interventions, as well as on radiological diagnostics and interventional radiology. The presence and the pattern of arch variants may increase the technical difficulty of surgical procedures, thus detailed evaluation of aortic arch anatomy is important for planning thoracic surgery and endovascular interventions.

The aim of this study was to present the anatomical variations of the aortic arch and its branches in a large group of patients using CTA and consequently to obtain data on their representation in our population.

The study population included 550 patients with referral diagnoses requiring CTA chest radiography, which visualizes the aortic arch.

The anatomic features of the aortic arch itself and supra-aortic vessels were analyzed, and anatomical variations were recorded on each CT image.

The results showed that 91.3% of the patients had the usual pattern of the aortic arch, 8.7% had variations in the number of the supra-aortic vessels. The most common variation of the number of the aortic arch branches was their reduction to two, with left common carotid artery arising from brachiocephalic trunk (5.63%).

The knowledge of the anatomy of the aortic arch and its branches and identification of arch anomalies allow accurate surgical and intervention planning and helps avoiding potential complications.

Key words: aortic arch, variations, anatomy

Introduction

Anatomical variations of the aortic arch and its branches attract the attention for their analysis from anatomical and embryological aspect [1, 2, 3, 4, 5]. They may be associated with vascular rings, congenital heart disease, and chromosomal abnormalities. These variations can also have important implications on prognosis and management of surgical interventions, as well as on radiological diagnostics and interventional radiology [6, 7, 8]. The presence and the pattern of arch variants may increase the technical difficulty of surgical procedures, thus detailed evaluation of aortic arch anatomy is important for planning thoracic surgery and endovascular interventions [9, 10].

Modern radiological techniques such as computerized tomographic angiography (CTA) and magnetic resonance angiography provide an insight into the state of the aortic arch and allow an individual approach to each patient. CTA is a noninvasive technique that enables rapid and high-spatial-resolution evaluation of vascular anomalies along with assessment of tracheal or esophageal compression. Disadvantages of CT angiography include radiation exposure and a relatively high rate of intravenous contrast medium injection [11, 12].

The aim of this study was to present the anatomical variations of the aortic arch and its branches in a large group of patients using CTA and consequently to obtain data on their representation in our population.

Material and methods

This study was part of a project which aim was to present the morphological features and variations of the aortic arch and its branches in the Macedonian population.

The study population included 550 patients referred to the University Clinic for Surgical Diseases "St. Naum Ohridski" in Skopje for CTA during October 2016 to October 2017. The study

included patients from both sexes, older than 18 years, with referral diagnoses requiring CTA chest radiography, which visualizes the aortic arch (arterial diseases and aneurysm of the aorta, traumatic vascular chest injury, pulmonary embolism). The collection of images was made by a specialist radiologist involved in the study.

Before the examination, the patients had been informed that their recordings would be used for the purposes of a research study, and they signed a written consent. The CTA was obtained using a MDCT scanner BrightSpeed GE 16 slices. In order to make a successful visualization of the blood vessels, the patients were appropriately prepared for the examination. They were told to be hungry 4 to 8 hours before the examination. During the procedure the patients were lying on the CT table in supine position and were advised to stay calm. The scan started at the level of thoracic inlet to include the proximal parts of the carotid and subclavian arteries and ended below the diaphragm. The slice thickness was 0.6 mm. Contrast material was injected through an 18- to 20-gauge IV catheter inserted into an arm vein, a total of 100 ml at a rate of 3 ml/s with a pressure injector, followed by a flush of 40 ml of saline administered at the same injection rate. After the contrast medium was injected, scanning was carried out automatically by using a bolus tracking software. Data were transferred to a workstation for post-processing. Reconstruction included the following: maximum intensity projection-MIP; four-dimensional CTA with volume rendering; multiplanar reformation-MPR. SYNGO software was used for post-processing (analysis). The course of the aortic arch was clearly observed in all of the 550 patients. Each of the CT images was analyzed by 2 independent examiners.

The anatomic features of the aortic arch itself and supra-aortic vessels were analyzed, and anatomical variations were recorded on each CT image.

Results

The analysis of the 550 CTA images showed that 502 of them (91.3%) had the usual pattern of the aortic arch giving rise to 3 large vessels: brachiocephalic trunk, left common carotid artery and left subclavian artery (Fig. 1).

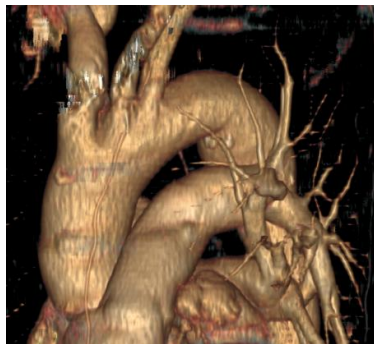


Figure 1. Usual pattern of the aortic arch.

Among the 550 patients that were analyzed, 48 (8.7%) had variations in the number of the supra-aortic vessels. The examination showed that the most common variation of the number of the aortic arch branches was their reduction to two, with left common carotid artery arising from brachiocephalic trunk (31 of the analyzed CTA images or 5.63%) (Fig. 2).

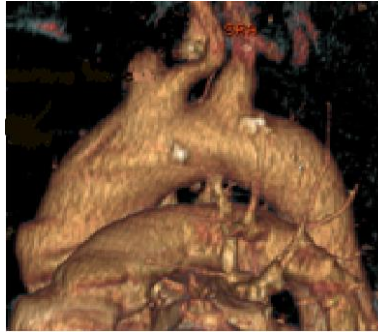


Figure 2. Left common carotid artery arising from brachiocephalic trunk

Seventeen of the patients (3.09%) had aortic arch with four branches, with separate origin of the left vertebral artery between the left common carotid and the left subclavian artery (Fig. 3).

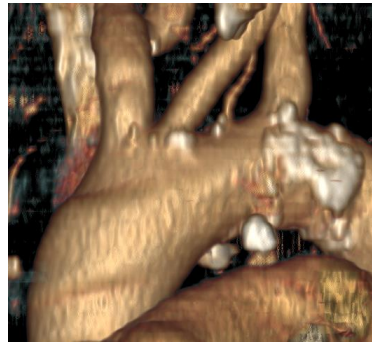


Figure 3. Separate origin of the left vertebral artery between the left common carotid and the left subclavian artery

Examination of the aortic arch itself did not reveal double, interrupted or right-sided arch.

Discussion

Aortic development is a complex process, which can lead to a variety of congenital variants and pathologic anomalies [12]. The anatomy of the normal left aortic arch can be described by persistence or regression of segments of the hypothetical double aortic arch system proposed by Edwards [12]. According to this theoretical model consisting of bilateral arches and arterial duct encircling the trachea and esophagus, the potential contributions of nearly all embryonic arches to components of the definitive adult arch system can be explained. It is possible by postulating regression of a segment that would normally persist, and/ or persistence of a segment that would normally regress [12, 13].

The normal left aortic arch results from regression of the distal right fourth arch between the right subclavian artery and the descending aorta, including the right ductus arteriosus, and the right dorsal aorta distal to the origin of the seventh intersegmental artery. The remaining proximal aspect of the right fourth arch forms the proximal portion of the right subclavian artery, and the left fourth arch forms the definitive aortic arch. The distal right subclavian artery is derived from a portion of the right dorsal aorta and the right seventh intersegmental artery. The left subclavian artery is derived entirely from the left seventh intersegmental artery. The normal left arch crosses the left main bronchus at the level of the T5 vertebral body. The descending thoracic aorta is usually to the left of the midline.

Anatomic variations of the aortic arch and large vessels are well documented as seen during autopsies, anatomical and clinical studies. The most common pattern in the origin of the large vessels of the aortic arch is where the brachiocephalic trunk is the first and the largest vessel arising from the aortic arch, followed by the left common carotid artery and left subclavian artery. Direct branches of the aortic arch are also known as primary or supra-aortic arteries. The distance between these origins varies, the most frequent being approximation of the left common carotid artery to the brachiocephalic trunk.

There are several variations of aortic arch branching patterns that can occur in a left aortic arch. The results obtained in our study showed that 91.3% of the examined patients had the usual pattern of the aortic arch giving rise to 3 large vessels. The most common variation of the aortic arch pattern was reduction of the number of the branches to two, with left common carotid artery arising from brachiocephalic trunk (5.63%). Aortic arch with four branches, with separate origin of the left vertebral artery between the left common carotid and the left subclavian artery was present in 3.09% of the patients. We did not find double, interrupted or right-sided arch.

According to the literature there are diverse data about the percentage of the representation of the aortic arch variations [1,14, 15, 16, 17]. However, the most common variation of the branching pattern occurs when the left common carotid artery has a common origin with, or arises directly from the brachiocephalic trunk. Another relatively common arch variation is the left vertebral artery arising directly from the aortic arch proximal to the left subclavian artery. According to Moore, the most frequent variation of the aortic arch is the common trunk of brachiocephalic trunk and left common carotid artery (11%). Hanemman *et al.* found out that a common origin of the brachiocephalic trunk and left common carotid arteries, and direct origin of the left common carotid artery from the brachiocephalic trunk, have prevalence of 13% and 9% in the general population, respectively [12]. The same authors registered prevalence of 5% and 6% for the left vertebral artery arising directly from the aortic arch proximal to the left subclavian artery. According to Gray's anatomy primary branches may be reduced to two with left common carotid artery arising from the brachiocephalic trunk in 7% of the population [14]. An analysis of variations in branches from 1000 aortic arches made by Anson in 1963 showed the usual arch pattern in 65%, and in 27% the left common carotid artery shared the brachiocephalic trunk [16, 17]. An analysis made by Saadoon Kadir showed that 70% of the population had the usual pattern of the aortic arch [16, 17]. The most frequent variation was arising of the brachiocephalic trunk and left common carotid artery from common trunk (22%). In the same study, about 6% of analyzed cases had separate arising of left vertebral artery. According to Grant, the most common variations, which represent 73% of all variations of the number of aortic arch branches, are common trunk of brachiocephalic trunk and left common carotid artery (15%), and arising of the left common carotid artery from brachiocephalic trunk (7%) [16, 17]. In the study comprising 1265 patients conducted by Vu urevi *et al.* the common vascular pattern was present in 74.72%. The origin of the left common carotid artery from the brachiocephalic trunk was the most frequent variation, which occurred in 15.56% of patients, and the left vertebral artery arising directly from the aortic arch proximal to the left subclavian artery was found in 3.63% of patients in their study [1].

Conclusion

The most frequent variations of the aortic arch pattern in this study were the origin of the left common carotid artery from the brachiocephalic trunk and the left vertebral artery arising directly from the aortic arch proximal to the left subclavian artery. The knowledge of the anatomy of the aortic arch and its branches and identification of arch anomalies allow accurate surgical and intervention planning and helps avoiding potential complications.

References

1. Vu urevi G, Marinkovi S, Pu-ka- L, Kova evi I, Tanaskovi S, Radak D, Ili A. Anatomy and radiology of the variations of aortic arch branches in 1,266 patients. *Folia Morphol.* 2013; 72(2):113622.
2. Bhatia K, Ghabriel MN, Henneberg M. Anatomical variations in the branches of the human aortic arch: a recent study of a South Australian population. *Folia Morphol* 2005; 64: 2176 224.

3. Cheng M, Xiadong X, Wang C, You C, Mao B, He M, Zhang C. Two anatomic variations of the vertebral artery in four patients. *Ann Vasc Surg* 2009; 23: 689, e165.
4. Natsis K, Didagelos M, Manoli SM, Papathanasiou E, Sofidis G, Anastasopoulos N. A bicarotid trunk in association with an aberrant right subclavian artery. Report of two cases, clinical impact, and review of the literature. *Folia Morphol* 2011; 70: 68673.
5. Sadler TW. Cardiovascular system. In: Sadler TW ed. *Langman's medical embryology*. 10th Ed. Lippincott Williams Wilkinson, a Wolters Kluwer business, Philadelphia, 2006, pp. 1596194.
6. Atkin GK, Grieve PP, Vattipally VR, Ravikumar KH, Das SK. The surgical management of aortic root vessel anomalies presenting in adults. *Ann Vasc Surg* 2007 21: 525634.
7. Cin CS, Arena GO, Bruin G, Clase CM. Kommerell's diverticulum and aneurysmal right-sided aortic arch: A case report and review of literature. *J Vasc Surg* 2000; 32:1208614.
8. Fazan VPS, Ribeiro RA, Ribeiro JAS, Filho OAR. Right retroesophageal subclavian artery. *Acta Cirurg Bras* 2003; 18 (5): 5466.
9. Kumar S, Pamidi N, Somayaji SN, Nayak S, Vollala VR. Anomalous branching pattern of the aortic arch and its clinical applications. *Singapore Med J* 2010; 51:e1826e183.
10. Natsis KI, Tsitouridis IA, Didagelos MV, Fillipidis AA, Vlasis KG, Tsikaras PD. Anatomical variations in the branches of the human aortic arch in 633 angiographies: clinical significance and literature review. *Surg Radiol Anat* 2009; 31: 319623.
11. Nakhla OL. Role of multi- slice CT angiography in the evaluation of conotruncal anomalies. *The Egyptian Journal of Radiology and Nuclear Medicine* 2015; 46: 37167.
12. Hanneman K, Newman B, Chan F. Congenital variants and anomalies of the aortic arch. *Radiographics* 2017; 37(1):32-51.
13. Kau T, Sinzig M, Gasser J et al. Aortic development and anomalies. *Semin Intervent Radiol* 2007;24(2):141652.
14. Williams PL, Bannister LH, Berry MN, Collins P, Dyson M, Dussek JE, Ferguson MWJ. *Gray's anatomy*. 38th ed. New York: Churchill Livingstone; 2006.
15. Moore KL, Dalí AF, Agur AMP. *Clinically Oriented Anatomy*. 9th Edition. Skopje: Tabernakul; 2011.
16. Zhivadinovik J. Morphology and developmental anatomy of aortic arch. *Acta morphol*. 2010; 7 (2): 16-22.
17. Zhivadinovik J. Morfologija na aortniot lak kaj novorodeni i mrtvorodeni. [magisterski trud] Skopje: Medicinski fakultet; 2000.