JMS 2024; Vol7 (3):178-183
UDC: 616.314.16-006.2
doi.org/10.55302/JMS2473178p

LARGE MAXILLARY RADICULAR CYST (CASE REPORT)

Dejan Panev[1], Irena Stojanova[2], Kiro Papakocha[3], Mirjana Markovska Arsovska[3], Vancho Spirov[3]
[1]PZU Dental Art Studio – Stip, Republic of North Macedonia
[2]Department of Oral Surgery, University Dental Clinical ss.Pantelejmon. Skopje, Republic of North Macedonia
[3]Faculty of Medical Sciencies. University Goce Delchev Stip. Republic of North Macedonia

Abstract

A cyst is defined as a pathological cavity lined by epithelium and the lumen is filled with cystic contents. Radicular cysts are most common odontogenic cysts and they are usually associated with carious, nonvital or fractured teeth.

Many of them are usually asymptomatic and can be detected incidentally on routine radiography before the symptoms appear. Symptoms appeared when they are acutely inflamed. Radiologically, it arises from the apex of the root of a tooth and is bounded by a thin rim of cortical bone. The diagnosis of a cyst, in addition to clinical and paraclinical examinations must be confirmed by the histopathological findings.

We present a case of a radicular cyst in the maxilla that exists a few years. 41 years old female patient has painless swelling that manifests extra-orally in the upper left buccal region. It has been recurring in recent years but the condition was improving with the administration of antibiotic therapy. Surgical treatment of the cyst (cystectomy in toto) with tooth extraction is the method of choice. Diagnosis and management of the patient are discussed.

Keywords: odontogenic cyst, radicular cyst, maxilla, cystectomy in toto, histopathologic analysis

Introduction

Odontogenic cysts are pathological cavities with epithelial lining and surrounded by fibrous connective tissue that originates from odontogenic tissues. The basic precondition for the occurrence of a cystic lesion is the previous presence of epithelial tissue at the site of future development of the cystic formation.

Radicular cysts are one of the most common odontogenic cysts and arise from epithelial so-called Malaise – residues in the periodontal tissue usually as a consequence of inflammation of the pulp. Radicular large cysts can be a subject of interest of many studies because if their etiopathogenesis, asymptomatic growth, as well as differential diagnostic from another various tumors and soft-tissue pathological lesions of the affected area.

Aim

The aim of this study is to present the presence and surgical treatment of large radicular cyst in the maxilla.

Case report

A 41-years-old female patient referred to the Clinic for oral surgery due to recurrent swelling on the left side of the maxilla with precise localization. The patient provides information on swelling that persist recent years but the condition was improving with administration of antibiotic therapy.

On general examination, the patient was apparently healthy. Intraorally, on palpation, the lesion was soft and fluctuant. The buccal vestibule was devoid. Lymph nodes were non-palpable. Tooth 23 was nonvital and tender to vertical percussion which is a sign of apical inflammation. (Figure 1)

Figure 1. Intraoral finding of radicular cyst

The patient was referred for X-ray examination. The Orthopantomography image **(Figure 2)** revealed the presence of a unilocular radiolucent cystic lesion with sclerotic border associated with teeth 23. There were also another present cystic lesions in the right side of the mandible.

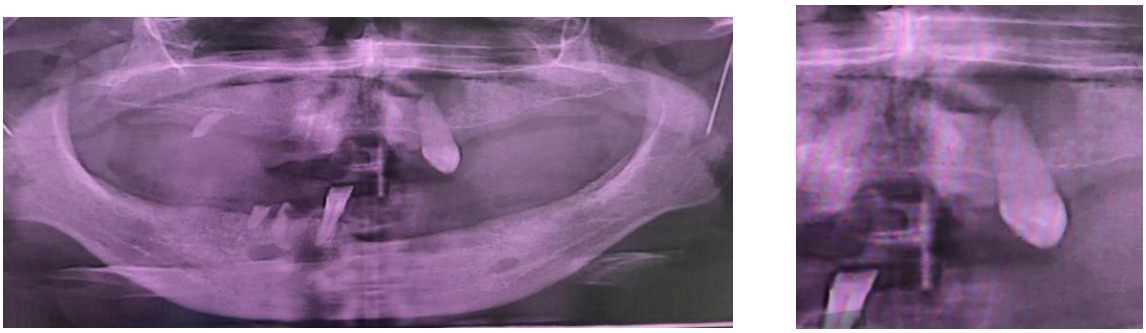

Figure 2. Radiographic 2D finding

Swelling, a buccal cortical break and expansion of the bone were obvious; these features indicated that the lesion was benign. After the clinical and radiological examination, a provisional diagnosis of the radicular cyst was made. Informed consent was obtained prior to oral surgery. Surgical intervention was carried out with a local anesthesia.

The surgical procedure began with disinfection of the operative field with a 1% solution of Betadine (providon-iodine), and then the application of anesthesia with mepivacaine (Scandonest3%) to anesthetize the operative field. The operative procedure began with an incision and formation of a trapezoidal mucoperiosteal flap (Figure 3) in order to obtain a visual control of the operative field.

The mucoperiosteal flap was raised in full thickness with a retractor, osteotomized in order to expose the cystic sacculus (Figure 4), extraction of tooth 23, cystic sacculus exposure and enucleation of the cyst in toto, cystectomy- Partch II (Figure 4)

After the enucleation of the cyst suture was performed (Figure 5). The material was put in 0.5% physiological solution (Figure 6), and was sent for histopathological examination at the Institute of Pathology for histopathological verification of the cyst and establishing the diagnosis-Radicular cyst. Sutures were placed (Figure 7). One gram of co-amoxicillin was used twice daily for one week as prophylaxis, and 90 mg etoricoxib (Etoxib) once daily to control the pain.The patient was followed up the next day, and the sutures were removed one week after the procedure (Figure 8). The postoperative course was without difficulties, and the gingival epithelization was obtained after 7 days.

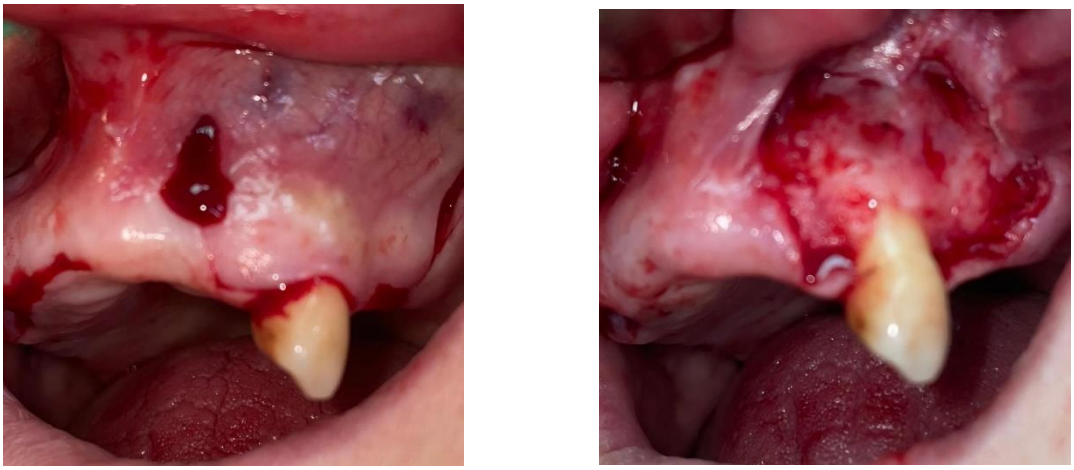

Figure 3. Formation of mucoperiosteal flap

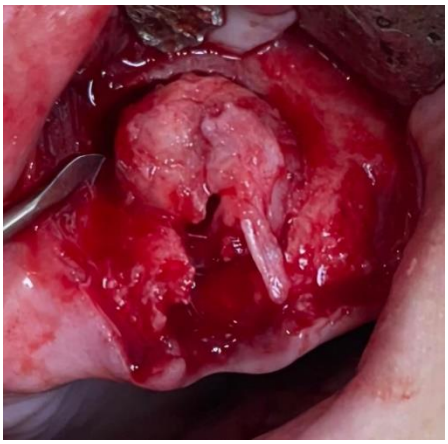

Figure 4. Exposed maxillary radicular cyst

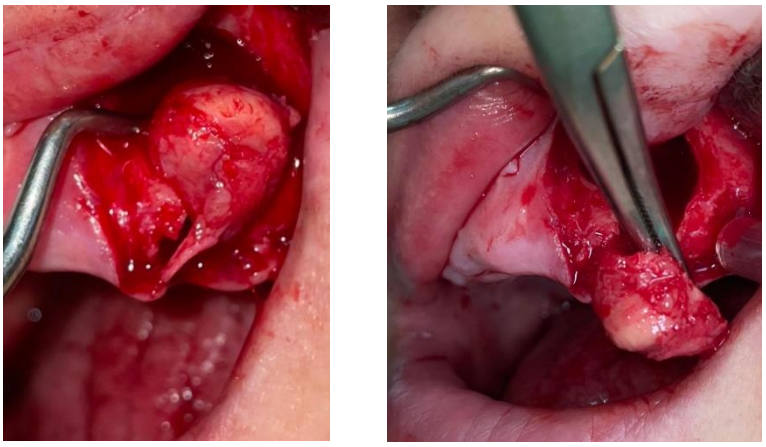

Figure 5. Enucleation of radicular cyst

Figure 6. Material taken for histopathological analysis

Figure 7. Sutures placed on the operative field

Figure 8. Wound healing after 7 days

After the obtained histopathological analysis, the diagnosis of a Radicular cyst was confirmed. (Figure 9)

МЕДИЦИНСКИ ФАКУЛТЕТ,
ИНСТИТУТИ , ИНСТИТУТ
ЗА ПАТОЛОГИЈА
ул.50-та Дивизија бр.6, 1000 Скопје
тел. 02/3-112-166

НАОД: 1259425

Име: Пол: Женска
Презиме ...
Роден: 04.07.1983
Адреса: 6 25
Град: ЦВЕТОВО

Установа: Стоматолошки клиники - ОРАЛНА ХИРУРГИЈА
Адреса:
Град: СКОПЈЕ
Лекар: ИРЕНА СТОЈАНОВА
Амб.број:
Прим./Зат.: 15.10.2024 - 13.11.2024

Клиничка дијагноза: Cystis radicularis maxillae lat. sin.
Вид на испратен материјал: Operative Material
Материјал опис :

ХИСТОПАТОЛОШКИ НАОД

CYSTIS RADICULARIS

K04.8 - K04.8

Макроскопски наод :
Доставена е отворена перцијално колабирана циста со пречник 1,2см и вид со дебелина 0,2-0,3см, жолтеникаво пробоена. Материјалот е целосно вклопен во 1 калап за ПХА.

Микроскопски наод:
Микроскопски на исеоците се гледа вид од радикуларна циста во дел со денудиран епител и зона на фиброза со вклопени холестерински кристали. Во дел се гледа обилно гранулациско ткиво со мешан мононјадрен воспалителен инфилтрат.
Наодот одговара за дел од вид на радикуларна циста.

Лекар:

Раководител
Проф. д-р Костадинова-Куновска
Славица
738379

Консултант

Патолог:
Проф. д-р Петрушевски Горјанка
738310

Figure 9 Histopathological finding

Conclusion

In conclusion, a radicular cyst is a common lesion affecting the jaws. In this case report, definitive diagnosis for a large maxillary lesion can be determined as a radicular cyst only after histopathological examination and verification. It was necessary to undertake invasive surgical treatment of the radicular cyst to prevent the development of jaw bone complications. This case report confirms the importance of early detection of a large radicular cyst and the effectiveness of its therapy.

Discussion

A wide variety of cysts and neoplasms may occur in the maxillofacial region, and their identification can be difficult. The most important of these are maxillary cysts [1].

A cyst is a pathological cavity with a defined wall of connective tissue and an epithelial carpet, filled with liquid, semiliquid or gaseous content. Growth of a cyst is typically slow, centrifugal and infiltrative. [2]

Radicular cysts are thought to arise from epithelial cell rests of Malaise islets in the periodontal ligament, and they are believed to proliferate as a result of periapical inflammation caused by infection of the root canal system. They are particularly frequent in the maxillary anterior region, presumably as a result of trauma. [3]

Radicular odontogenic cysts are the most commonly occurring odontogenic cysts of the jaws. From a pathogenetic point of view, in odontogenic inflammatory cysts there is inflammation usually from the root canal of the teeth. The basic precondition for the occurrence of a cystic lesion is the previous presence of epithelial tissue at the site of future development of the cystic formation. The epithelium for odontogenic inflammatory cysts originates from the remains of Hertwing's membrane found in the periodontium of the teeth, and is a consequence of its complete disintegration [4].

These collections of epithelium are called epithelial islets of Malaise and they are in a state of rest until some stimulus acts on them.Under the influence of bacteria and their products or under the influence of some other factors (mechanical, chemical and antigens), the metabolic activity of these cells changes and their proliferation begins. It follows from this that the basic prerequisite for the appearance of inflammatory cysts is the previous presence of an epithelium at the site of cyst development and an inflammatory stimulus. The radicular cysts are usually asymptomatic unless secondarily infected [5].

Commonly encountered odontogenic lesions are periapical abscesses, radicular cysts, dentigerous cysts, ameloblastoma, and odontogenic keratocysts. The treatment of radicular cysts in most cases is

surgical. The possibilities for such treatment and the choice of surgical method depend on the size of the cyst, its location, and the pathological formation.

Radicular cyst rarely exceeds 1 cm in size, but if larger it might show buccal cortical plate expansion and can thin the bone around the tooth [6]. Prompt diagnosis and treatment ensure the great success of the procedure [7]. The usual surgical treatments for radicular cyst include total enucleation of small lesions, marsupialization for decompression of larger cysts or a combination of these techniques. Should surgical intervention become necessary, the clinician must decide whether to raise a flap and completely enucleate the lesion or to try "decompression" first [8,9].

If marsupialization with decompression is attempted first, the size of the lesion will be reduced, which will make it less difficult to remove, with less risk of damage to the associated teeth and vital structures. For the case reported here, the surgical literature clearly indicated enucleation of the cyst as the preferred option, because marsupialization carries the risk that any cystic cells left behind may become malignant [10, 11]. However, for this patient, it was felt that cystectomy was the best treatment option.

References

1. Nair PN, Sundqvist G, Sjögren U. Experimental evidence supports the abscess theory of development of radicular cysts. Oral Surg Oral Med Oral Pathol Oral Radiol Endod. Epub 2008 Jun 13. 2008;106(2):294-303.
2. Asián-González E, Pereira-Maestre M, Conde-Fernández D, Vilchez I, Segura-Egea JJ, Gutiérrez-Pérez JL. Dentigerous cyst associated with a formocresol pulpotomized deciduous molar. J Endod. Epub 2007 Jan 4. 2007;33(4):488-92.
3. Lin LM, Huang GT, Rosenberg PA. Proliferation of epithelial cell rests, formation of apical cysts, and regression of apical cysts after periapical wound healing. J Endod. Epub 2007 Apr 2.2007;33(8):908-16.
4. Bernardi L, Visioli F, Nör C, Rados PV. Radicular Cyst: An Update of the Biological Factors Related to Lining Epithelium. J Endod. 2015 Dec;41(12):1951-61.
5. Colić S, Jurisić M, Jurisić V. Pathophysiological mechanism of the developing radicular cyst of the jaw. Acta Chir Iugosl. 2008;55(1):87-92.
6. Sevekar S, Subhadra HN, Das V. Radicular cyst associated with primary molar: surgical intervention and space management. Indian J Dent Res. 2018; 29:836–839.
7. Hamied, M. A.-S., Al-Shaikhani, S.M., Ali, Z. D. Inflammatory Odontogenic Cysts. AL-Kindy College Medical Journal, 2021.17(3), 135–144.
8. Lin LM, Huang GT, Rosenberg PA. Proliferation of epithelial cell rests, formation of apical cysts, and regression of apical cysts after periapical wound healing. J Endod. 2007 Aug;33(8):908-16.
9. Bruna Castilho Canassa, Angelo Jose Pavan, Inflammatory odontogenic cysts, a brief literature review Journal of surgical and clinical dentistry,2014 ;7,20-28.
10. Schneider LC. Incidence of epithelial atypia in radicular cysts: a preliminary investigation. J Oral Surg. 1977;35(5):370-4.
11. Mejia JL, Donado JE, Basrani B. Active nonsurgical decompression of large periapical lesions – 3 case reports. J Can Dent Assoc. 2004;70(10):691-4.