

OVERLAP SYNDROME IN REFRACTORY CASE

Filip Gucev¹, Snezhana Perchinkova-Mishevska¹, Georgi Bozhinovski¹,
Ljubinka Damjanovska¹

¹University Clinic of Rheumatology, Faculty of Medicine, Sts.Cyril and Methodius
University in Skopje, R. North Macedonia

Abstract

This is a report of the case of a 23 years-old girl with refractory dermatomyositis, complications in her treatment and the unfortunate fatal end.

Dermatomyositis can be a notoriously difficult disease to treat, and remission is often elusive or short-lived despite aggressive therapy. In the years after the diagnosis, many aggressive modalities of treatment were tried, including rituximab.

The patient had frequent exacerbations of the myositis, needed aggressive therapy and developed many side effects associated with the treatment.

Most common of these were infections. After suffering severe stress, she developed fever, was diagnosed with sepsis and despite exhaustive treatment at the intensive care unit she passed away.

Key words: dermatomyositis, refractory, immunosuppression, sepsis.

Introduction

Dermatomyositis is a chronic, systemic autoimmune inflammatory disorder primarily affecting the proximal muscles and the skin [1,2].

It is a distinctive disease accompanied by a characteristic rash occurring after, or more often preceding, muscle weakness [3,4].

The weakness can be mild, moderate, or severe enough to lead to quadriparesis.

In this report we present a patient with a refractory case of dermatomyositis which was resistant to aggressive immunosuppressive treatment.

Case Report

A 17-year-old female (figure 1) complaining of weakness and fatigue, a 1-month history of progressive maculo-papular rash over both legs and arms and fever (up to 38°C) was admitted to our Clinic.

Hematological analysis showed a hemoglobin level of 151g/L, white blood cell count 7,200/mm³, red blood cell count 4.9x10⁴/mm³.

Blood chemistry tests showed an elevated creatinine phosphokinase (CPK) of 11,352U/l, lactate dehydrogenase (LDH) 3,255U/l, alanine aminotransferase (ALT) 646U/l, aspartate aminotransferase 772U/l, creatinine 37mcmol/l.

Regarding serology, ANA Hep-2 and anti-Jo-1 were negative. Thyroid function was normal. Chest x-ray and abdominal ultrasound were normal.

Electromyography showed myogenic changes to right deltoid muscle. The right deltoid muscle was biopsied, and pathology results confirmed the diagnosis of dermatomyositis (figure 2).

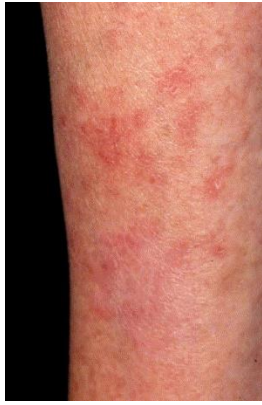

Figure 1. Maculo-papular rash.

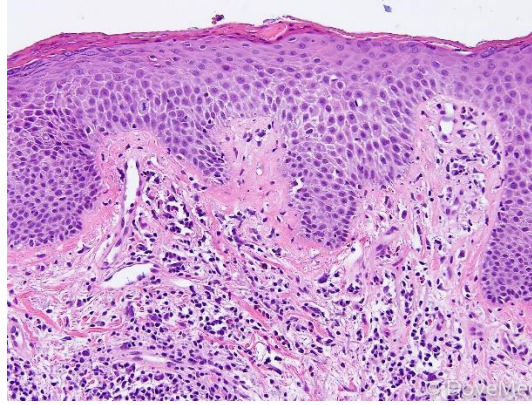


Figure 2. Histopathological finding of dermatomyositis.

Treatment with 60mg prednisolone daily and methotrexate (15mg/weekly) was started. Patient was kept on 60mg prednisolone daily for one month before starting the taper. Skin and muscle symptoms improved and she was discharged from hospital with significantly improved muscle strength and a CPK level of 729U/l.

The dose of methotrexate was increased to 20mg per week and patient was symptom free after one month.

Within three months, as the dose of prednisolone was reduced to 30mg daily, patient reported malaise and weakness. CPK levels had risen to 4409U/l.

It was decided to add azathioprine (2mg/kg) to the treatment and to start a new taper of prednisolone from 60mg daily, tapering by 5mg every 10 days. Patient was kept at 60mg prednisolone daily for two weeks before starting the taper this time.

The patient's condition improved, skin changes were significantly better and muscle strength improved. Minimum CPK level achieved was 859U/l.

Patient was again without complaints during the taper until a dose of 20mg prednisolone was reached. At that time, she complained of weakness and had a CPK level of 3689U/l. Thyroid function tests showed hypothyroidism.

An endocrinologist was consulted and therapy with levothyroxine started.

Patient's condition deteriorated, so it was decided to stop azathioprine and treat the patient with rituximab. The biologic agent was applied in two doses of 1000mg i.v., separated by 14 days. Prednisolone was again increased to 60mg daily, this time tapered immediately by 5mg weekly until 20mg daily.

Methotrexate was kept at 20mg per week. After 2 months of the application of rituximab, the patient was symptom free again. She reported no muscle weakness, and skin changes were minimal.

After six months, the patient was without complaints, CPK=520U/l. Rituximab was repeated using the same protocol as before.

Within a month, the patient developed an acute upper respiratory infection with fever as well as severe muscle weakness and a CPK level of 5587U/l. An attempt to stop corticosteroids was made in order to exclude possible corticosteroid induced myopathy.

This resulted in a significant deterioration of the patient's condition.

Therefore, a new prednisolone taper from 60mg daily was started. It was decided to stop methotrexate and start cyclosporine at 2mg/kg, which was increased to 3mg/kg within a month.

At that time her condition had again improved significantly, CPK=1335U/l.

The patient was treated with 3mg/kg cyclosporine, becoming symptom free, a minimum CPK level of 313U/l at 10mg prednisolone a day. Rituximab was not repeated since it was concluded that its effects on the patient were inconclusive and her condition had greatly improved.

After one year of treatment her condition deteriorated again. Due to the unavailability of IVIG in our country, treatment was continued with mycophenolate mofetil 2gr daily and the prednisolone was tapered from 60mg to 5mg a day.

In the following 18 months, the patient's condition had improved, but muscle weakness was significant, she was unable to rise from a chair or walk without assistance. CPK level was 189U/l and the patient was sent to the rehabilitation center for muscle strengthening treatment. This led to a gradual improvement of muscle strength.

After flooding in her village, she was admitted to hospital with fever. Blood culture showed coagulase negative, methicillin resistant staphylococcus. She was shifted to intensive care where after exhaustive treatment, the patient died.

Discussion

Patients with refractory dermatomyositis represent some of the most difficult cases for rheumatologist [5,6]. We kindly present this case of a young woman, treated aggressively with corticosteroids and multiple immunosuppressive medications including novel approaches such as rituximab [7-10].

During the treatment, she developed many side effects from the corticosteroid treatment such as facies lunata, stretch marks, hypertension, and infections were common. Upper respiratory infections such as rhinitis and pharyngitis were most common.

These were often triggers for exacerbations of the myositis. This circulus vitiosus of disease-treatment-immunosuppression-infection-exacerbation of the disease ended fatally for our patient as a result of sepsis.

References

1. Yang SH, Chang C, Lian ZX. Polymyositis and dermatomyositis - challenges in diagnosis and management. *J Transl Autoimmun.* 2019;2:100018. Published 2019 Oct 8. doi:10.1016/j.jtauto.2019.100018
2. Troyanov Y, Targoff IN, Tremblay JL, Goulet JR, Raymond Y, Senecal JL. Novel classification of idiopathic inflammatory myopathies based on overlap syndrome features and autoantibodies: analysis of 100 French Canadian patients. *Medicine (Baltimore)* 2005; 84: 231–49.
3. Bellutti Enders F, Bader-Meunier B, Baildam E, et al. Consensus-based recommendations for the management of juvenile dermatomyositis. *Ann Rheum Dis.* 2017;76(2):329-340. doi:10.1136/annrheumdis-2016-209247
4. Shu XM, Lu X, Xie Y, Wang GC. Clinical characteristics and favorable long-term outcomes for patients with idiopathic inflammatory myopathies: a retrospective single center study in China. *BMC Neurol* 2011; 11: 143.
5. Van de Vlekkert J, Hoogendijk JE, de Haan RJ, Algra A, van der Tweel I, van der Pol WL, et al. Oral dexamethasone pulse therapy versus daily prednisolone in sub-acute onset myositis, a randomised clinical trial. *Neuromuscul Disord* 2010; 20: 382–9.
6. Kishi T, Bayat N, Ward MM, et al. Medications received by patients with juvenile dermatomyositis. *Semin Arthritis Rheum.* 2018;48(3):513-522. doi:10.1016/j.semarthrit.2018.03.016
7. Bader-Meunier B, Decaluwe H, Barnerias C, Gherardi R, Quartier P, Faye A, et al, for the Club Rhumatismes et Inflammation. Safety and efficacy of rituximab in severe juvenile dermatomyositis: results from 9 patients from the French Autoimmunity and Rituximab registry. *J Rheumatol* 2011; 38: 1436–40.
8. Aggarwal R, Loganathan P, Koontz D, Qi Z, Reed AM, Oddis CV. Cutaneous improvement in refractory adult and juvenile dermatomyositis after treatment with rituximab. *Rheumatology (Oxford).* 2017;56(2):247-254. doi:10.1093/rheumatology/kew396
9. Oddis CV, Reed AM, Aggarwal R, Rider LG, Ascherman DP, Levesque MC, et al, and the RIM Study Group. Rituximab in the treatment of refractory adult and juvenile dermatomyositis and adult polymyositis: a randomized, placebo-phase trial. *Arthritis Rheum* 2013; 65: 314–24.
10. Unger L, Kampf S, Lütke K, Aringer M. Rituximab therapy in patients with refractory dermatomyositis or polymyositis: differential effects in a real-life population. *Rheumatology (Oxford).* 2014 Sep;53(9):1630-8. doi: 10.1093/rheumatology/keu024. Epub 2014 Apr 4.