

SUPERNUMERARY PREMOLARS IN MAXILLA AND CONCRESCEENCE OF ROOTS – case report

Daniela Srbinoska¹, Vesna Trpevska¹, Oliver Temelkov², Simona Simjanovska³,
Elizabeta Chadikovska⁴

¹Department of Orthodontics, University Dental Clinical Center "St. Panteleimon", Skopje,
R. North Macedonia.

²PHO Dr Snezana Temelkova -Veles, R. North Macedonia.

³Faculty of Dentistry, Ss. Cyril and Methodius University in Skopje, R. North Macedonia.

⁴Institute of Anatomy, Faculty of Medicine, Ss. Cyril and Methodius University in Skopje,
R. North Macedonia.

Abstract

The presence of supernumerary teeth is not uncommon in the general population. Supernumerary teeth (hyperodontia) appear more in permanent dentition. Supernumerary teeth which are in the premolar region occur more often in the mandible with different shape and size. They might occur singly or in multiples, be erupted or impacted. The reason of hyperodontia is still unknown. There are a lot of theories. Various theories have been suggested to explain the etiology of supernumerary teeth in general including both, the genetic theory and environmental factors.

Furthermore, it has been suggested that supernumerary premolar teeth belong to a third (postpermanent) series. Proliferation of dental lamina has been implicated. The presence of supernumerary teeth usually is connected with some disease or syndromes. Treatment of hyperodontia depends on the area where supernumerary teeth occur.

This article presents a case report of an 11-year-old girl with hyperodontia of the first premolar, erupted palatinally in the left side of maxilla. This is supplemental tooth that looks like the permanent premolar. The orthopantomogram and 3D radiograph showed a big possibility of concrescence of both premolars. To make a definitive diagnosis and a plan for orthodontic treatment, OPG and 3D radiograph were crucial.

Keywords: supernumerary teeth, concrescence, OPG, 3D radiograph, orthodontic treatment.

Introduction

Supernumerary teeth (SNT) are developmental anomaly that can occur in any area of the dental arch and can affect any dental organ. The term used to express SNT is referred to as hyperodontia. They can occur in primary or permanent dentition, but are more frequently reported in permanent dentition. SNT occur in different forms, unilaterally or bilaterally and either in the maxilla or mandible [1]. Ectopic eruption of SNT may obstruct the path of unerupted permanent tooth [2].

SNT can be classified on the basis of their morphology or position. On the basis of morphology, they are classified as:

1. Supplemental (where the tooth has normal shape like the teeth in the series).
2. Tuberculate (also called "barrel shaped").
3. Conical (also called "peg shaped").
4. Compound odontoma (multiple small teeth –like forms).
5. Complex odontoma (a disorganized mass of dental tissue) [3].

The "odontoma" refers to any tumor, which is composed of more than one tissue [4]. Based on the position, SNT may be classified as mesiodens, parapremolar, paramolar or distomolar [5]. SNT in the premolar region might occur singly or in multiples [6, 7]. The frequency of supernumerary premolars is high in orthodontic population and the age range of the patients detected with the supernumerary premolars is between eleven and sixteen years [8].

SNT are asymptomatic and therefore panoramic radiograph is very important for diagnosis and further plan of treatment [9]. Various theories have been suggested to explain the etiology of SNT including genetic and environmental factors [10, 11].

Most of SNT had complete root formation with possibility of concrescence from one small part from the solid cemental mass or along the entire root surfaces [6, 8, 12-14, 15-21]. Concrescence can occur between two adjacent normal teeth or it can also happen between a normal tooth and a SNT [22].

Lack of space for the tooth during eruption can be the reason for concrescence. Transposed supernumerary premolars have also been reported [7, 21, 23, 24]. Furthermore, cases of fusion between supernumerary premolars and the adjacent teeth have been reported [25, 26]. Prior to the start of orthodontic treatment, orthopantomographic analysis is required, to make a definitive diagnosis and a plan for treatment [2, 8, 12, 27].

Case report

An 11-year-old female with permanent dentition was brought to our clinic for orthodontic treatment. The patient's chief complaint was discomfort in her upper jaw. The patient had no complaint of pain, no signs of infection and was in a good general health. Intraoral clinic examination revealed SNT of permanent first premolar erupted palatally in maxilla and lateral open bite due to position of her tongue. Both of the teeth were divided with incisura. On orthopantomogram we saw that the roots were not divided. Due to the fact that panoramic radiograph as a two-dimensional technique gives us limited information, we made 3D radiograph to collect more precise information. 3D radiograph showed that the roots of both premolars were divided (Fig. 1).

We consulted an oral surgeon for SNT extraction who denied the intervention of extraction because of the possibility of concrescence. Also, the clinical examination revealed Class II, division 1 malocclusion, the overjet was 6 mm and overbite 3 mm and the patient had presence of infant swallowing (Fig. 2).

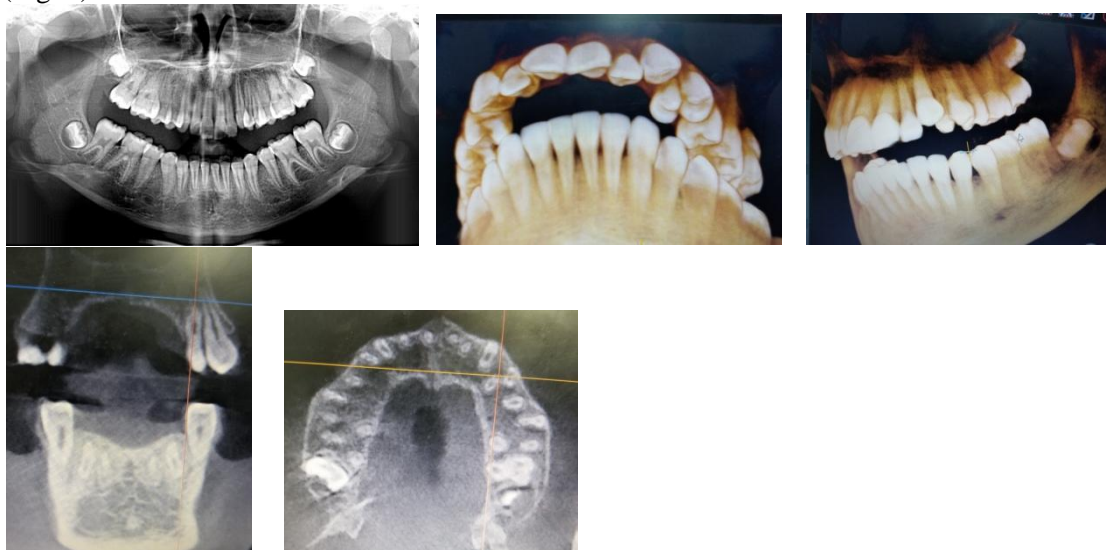


Figure 1. Orthopantomogram and 3D radiograph of the patient

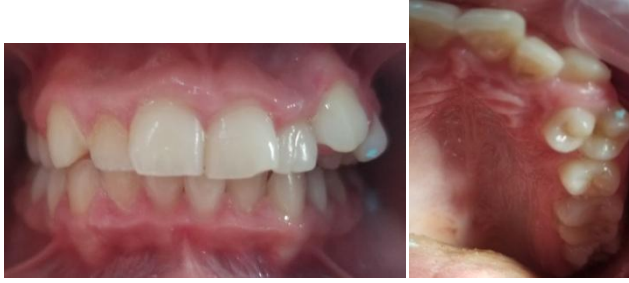

Figure 2. Intraoral view of the patient

Plan of therapy

The clinical management of this patient was necessary and the orthodontic treatment included few steps. The orthodontic treatment was started in order to correct the bad oral habit (tongue posture up in the premolar region) and to correct infant swallowing with myofunctional therapy.

We made individual functional orthodontic appliance to correct dental disorder (lateral open bite) and dysfunction of the tongue and we advised some myofunctional exercises (Fig. 3).

This therapy gives excellent results if the patient uses the appliance 4-5 hours per day and during the night. The second step in our treatment was to monitor our patient in order to decide whether to extract the SNT. Extraction of the SNT in this phase was dangerous due to concrescence to lose teeth, the SNT and the permanent first premolar.

That would compromise our treatment, which was confirmed with a 3D radiograph.

Losing both teeth from the left premolar region of maxilla would result in necessary extraction of the first premolar on the right side and consequently in placement of fixed orthodontic appliance.

Thus, we agreed that the best plan of orthodontic treatment in this patient was to change the poor oral habits and to improve oral dysfunction.

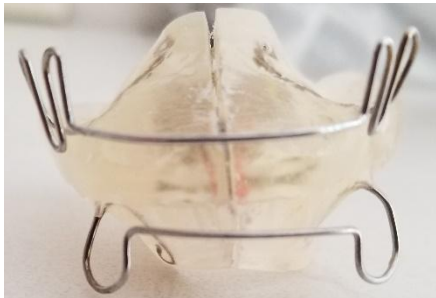

Figure 3. Myofunctional individual orthodontic appliance

Discussion

There were several cases of late-developing supernumerary premolars [LDSP] discussed in the literature [26, 27-32].

Most of these cases were not detected in patients younger than 14 years. SNT could delay the eruption of the adjacent tooth or cause cystic lesion and root resorption [33, 34].

The choice to or not to extract the SNT was mainly due to the damage that the tooth might cause. The literature shows that 76-86% of non-syndromic cases involve only one SNT and that 12-23% of cases present two SNT [35, 36, 37].

Many hypotheses have been proposed to explain the development of those teeth [38] including atavism tooth germ dichotomy, hyperactivity of dental lamina and genetic factors.

The most frequent location of the SNT is in the anterior region of the maxilla (mesiodens) and very rarely like in our case, in the premolar region.

The clinical management of patients with SNT depends on multiple parameters. Cooperation between orthodontist and oral surgeon is necessary and very important to eliminate onset of any complications [35].

Conclusion

The initiation and the genetic control of tooth formation, the mechanisms of creation the SNT formation are still unclarified. The exact etiology of SNT formation might be clarified in the future based on stem cell biology.

The protocol of treatment is correction of poor oral habits with myofunctional appliance and monitoring the patient to finally make the decision on extraction of the SNT at the appropriate time.

Based on the literature, we can conclude that SNT in the premolar region of the maxilla is a very rare condition

References

1. Meighani G, Pakdaman A. Diagnosis and management of supernumerary (mesiodens): a review of the literature. *J Dent (Tehran)* 2010 Winter; 7(1):41-9.
2. Garvey MT, Barry HJ, Blake M. Supernumerary teeth -an overview of classification, diagnosis and management. *J Can Dent Assoc.* 1999; 65:612-16.
3. Schmuckli R, Lipowsky C, Peltomaki T. Prevalence and morphology of supernumerary teeth in the population of a Swiss community. Short communication. *Schweiz Monatsschr Zahnmed.* 2010; 120(11): 987- 93.
4. Howard RD. The unerupted incisor. A study of the postoperative eruptive history of incisors delayed in their eruption by supernumerary teeth. *Dent Pract Dent Rec*1967; 17: 332-41.
5. Arathi R, Ashwin R. Supernumerary teeth: a case report. *J Indian Soc. Pedod. Prev Dent.* 2005 Jun; 23(2):103-5.
6. S. V. Hegde and A. K. Munshi. "Late development of supernumerary teeth in the premolar region: a case report", *Quintessence International*, vol. 27, no.7, pp.479-481, 1996.
7. P.J. Scanlan and S.J. Hodges. Supernumerary premolar teeth in siblings. *British Journal of Orthodontics*, vol. 24, no.4, pp. 24297-24300, 1997.
8. L. K. Rubenstein , S. J. Lindauer, R. J. Issacson and N. Germane, "Development of supernumerary premolars in an orthodontic population", *Oral Surgery, Oral Medicine ,Oral Pathology*, vol. 71, pp. 392-395, 1991.
9. Bondemark L, Jepson M, Lindh - Ingildsen L, et al. Incidental findings of pathology and abnormality in Pretreatment orthodontic panoramic radiographs. *Angle Orthod.*2006; 76: 98-102.
10. R.P.Anthonappa, N.M.King and A.B.M.Rabie. "Aetiology of supernumerary teeth: a literature review", *European Archives of Pediatric Dentistry*, vol.14, no.5, pp.279-288, 2013.
11. K. Khalaf, "Supernumerary teeth- review of aetiology, sequel, diagnosis and management. Part II, "International Journal of Advanced Research, vol.4, no.11, pp. 1363-1375, 2016.
12. E .C. Stafne, "Supernumerary teeth", *Dental Cosmos*, vol. 74, pp. 653-659, 1932.
13. C. Price and G. S. Hoggins. "A category of supernumerary premolar teeth". *British Dental Journal*, vol.126, pp. 224-228, 1969.

14. F. A. C. Oehlers, "Postpermanent premolars", *British Dental Journal*, vol.93, pp.157-158, 1952.
15. J. J. W. Breckon and S. P. Jones, "Late forming supernumeraries in the mandibular premolar region," *British Journal of Orthodontics*, vol.18, no.4, pp.329-331, 1991.
16. D. E. J. Bowden, "Post-permanent dentition in the premolar region," vol.131, no.3, pp.113-116, 1971.
17. G. A. Morgan, P. R. Morgan, and S. A. Crouch, "Recurring mandibular supplemental premolars. Oral Surgery," *Oral Surgery, Oral Medicine, Oral Pathology*, vol.30, pp.501-504, 1970.
18. R. Ranta and P. Ylipaavalniemi, "Developmental course of supernumerary premolars in childhood: report of two cases" *Journal of Dentistry for Children*, vol.48, no.5, pp.385-388, 1981.
19. M. L. Kantor, C. S. Bailey and E.J.Burkes, "Duplication of the premolar dentition". *Oral Surgery, Oral Medicine, Oral Pathology*, vol.66, no.1, pp. 62-64, 1988.
20. F. N. Hattab, O. M. Yassin, and M. A. Rawashdeh, "Supernumerary teeth: report of three cases and review of the literature," *Journal of Dentistry for Children*, vol.61, no.5-6, pp.382-393, 1994.
21. S. M. Cochrane, J. R. Clark and N. P. Hunt, "Late developing supernumerary teeth in the mandible," *British Journal of Orthodontics*, vol.24, no.4, pp.293-296, 1997.
22. Romito L (2004). Concrescence: Report of a rare case. *Oral.Surg. Oral.Med. Oral.Pathol. Oral.Radiol. Endod.* 97:325-327.
23. N. K.Vijayavergia, P.K.Dayal, and M.R Joshi, "Bilateral functioning premolar –form supernumerary teeth distal to the maxillary permanent first molars," *Journal of Dentistry*, vol.5, no.1, pp. 76-78, 1977.
24. D. M. Raphael, "Transposed supernumerary premolars". *Oral Surgery, Oral Medicine, Oral Pathology, Oral Radiology*, vol.46, no.4, pp.598, 1978.
25. F .C. Loh and J. F. Yeo, "Paramolar with bifid crown," *Oral Surgery, Oral Medicine, Oral Pathology*, vol.76, no.2, pp.257-258, 1993.
26. E. Nunes, I. G. de Moraes, P. M. de Novaes, and S.M.de Sousa, "Bilateral fusion of mandibular second molars with supernumerary teeth: case report," *Brazilian Dental Journal*, vol.13, no.2, pp.137-141, 2002.
27. J. W. Zvolanek and T. M. Spotts, "Supernumerary mandibular premolars, report of case". *Journal of the American Dental Association*, vol. 110, pp.721-723, 1985.
28. C. Turner and C. J. Hill, "Supernumerary mandibular premolar: the importance of radiographic interpretation," *Journal of Dentistry for Children*, vol.53, no.5, pp.375-377, 1986.
29. D. E. J. Bowden, "Post-permanent dentition in the premolar region," *British Dental Journal*, vol.131, no.3, pp.113-116, 1971.
30. N. Gibson, "A late developing mandibular premolar supernumerary tooth," *Australian Dental Journal*, vol.45, no.4, pp. 277-278, 2000.
31. R. S. Jamwal, P. Sharma, and R. Sharma, "Late-developing supernumerary mandibular premolar: a case report," *World Journal of Orthodontics*, vol.11, no.4, pp. 94-98, 2010.
32. S.Yassaei, M.Goldani Moghadam, and S. M. Tabatabaei, "Late developing supernumerary premolars: reports of two cases". *Case Reports in Dentistry*, vol.2013, Article ID 969238, 4 pages, 2013.
33. C. A. Frank, "Treatment options for impacted teeth," *Journal of the American Dental Association*, vol.131, no.5, pp.623-632, 2000.
34. A.Shah, D.S.Gill, C.Tredwin, and F.B.Naini, "Diagnosis and management of supernumerary teeth," *Dental Update*, vol.35, no.8, pp. 510-520, 2008.
35. Rajab LD, Hamdan MA. Supernumerary teeth: review of the literature and a survey of 152 cases. *Int. J. Paediatr Dent* 2002; 12:244-254.
36. Diaz A, Orozco J, Fonseca M. Multiple hyperodontia: report of a case with 17 supernumerary teeth with non -syndromic association. *Med Oral Patol Oral Cir Bucal* 2009; 14:E229-E231.
37. Fernandez Montenegro P, Valmaseda Castellon E, Berini Aytes L, Gay Escoda C. Retrospective study of 145 supernumerary teeth .*Med Oral Patol Oral Cir Bucal* 2006;11:E339-E344.

38. Takahashi,M.; Hosomichi K.; Yamaguchi, T.; Yano, K.; Funatsu, T.; Adel, M.;Haga, S.;Maki, K.;Tajima, A. Whole-exome sequencing analysis of supernumerary teeth occurrence in Japanese individuals. *Hum. Genome Var.* 2017, 4, 16046.