

## OSTEOMYELITIS OF FEMUR IN A DRUG ADDICTED CHILD

Kirovski Ilija, Micevska V, Sofijanovska A, Bojadzieva S, Naunova Timovska S, Jordanova O  
University Clinic of Pediatrics, Faculty of Medicine, Ss. Cyril and Methodius University Skopje,  
Republic of North Macedonia

### Abstract

One of the serious complications related to intravenous drug use is osteomyelitis. We report a 13-year-old male child with a history of intravenous heroin abuse, who was admitted to the hospital complaining of abdominal pain and pain in the left leg. Anteroposterior roentgenogram and CT scan of the left thigh and femur, confirmed the diagnosis of osteomyelitis. Pus culture was positive for *Staphylococcus aureus*.

Despite extensive antibiotic and anticoagulant therapy, the patient's clinical status improved very slowly. Surgical procedure was not undertaken. Femoral osteomyelitis due to injection drug use in childhood is an extremely rare and uncommon condition. Intravenous drug abuse, late-onset treatment, and secondary bacterial infection can lead to complications which occurred in the case presented. It is an extremely difficult condition to treat and is a real challenge for physicians.

The rapid response and participation of a multidisciplinary team of physicians is of particular importance.

**Key words:** Antibiotics, children, femur, osteomyelitis, *Staphylococcus aureus*

### Introduction

Intravenous drug abuse is a common social and medical problem, and can lead to considerable morbidity and mortality.

Fortunately, despite the fact that it occurs, injection drug abuse is rare in children.

The most common complications that occur with intravenous drug use are: skin and soft tissue infections, septic arthritis of joints, endocarditis, hepatitis B and C, all of which may cause pain, disability and be life threatening. Osteomyelitis, as complication in that age group, is of particular importance [1].

### Case report

A 13-year-old boy, smoker, with a history of intravenous drug abuse (heroin addict) was admitted to the hospital, with a one-week history of acute abdominal pain and pain in the left leg. No fever was noted at admission. There was no history of trauma. Physical examination showed tenderness over the lower abdomen. Old stab wounds were present in the groin area. He was examined by a pediatric surgeon who considered it to be appendicitis and an appendectomy was performed.

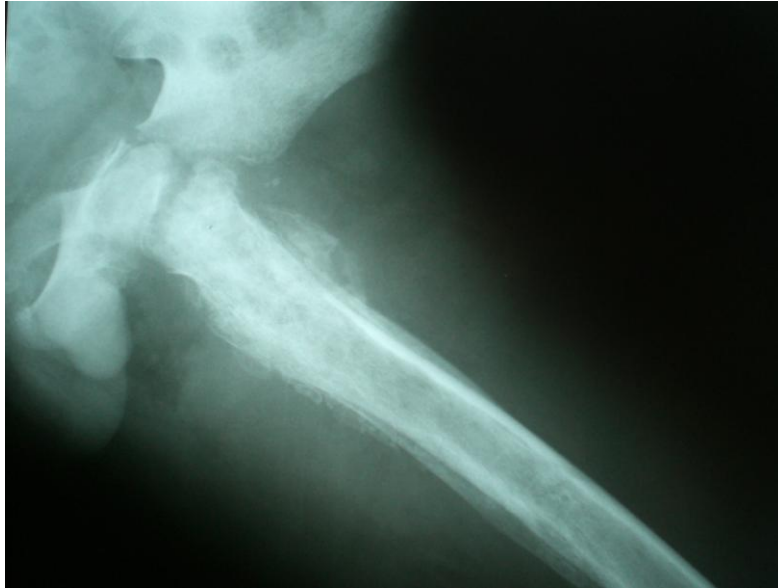An uninflamed appendix at appendectomy was found. After surgery, he received antibiotic combination of third-generation cephalosporin (cephtriaxone) and an aminoglycoside (amikacin), as well as analgesic and sedative medications. Due to low values of potassium and calcium, substitution with the same was performed. Anticoagulant treatment was administered as well. The first days in hospital he was very upset, at times aggressive, and had hallucinations.

Two weeks after surgery, the patient escaped and during that period he was drugged intravenously with heroin. After a while, he was readmitted to the hospital. On the second admission, a few fresh injection-related wounds in the left inguinal region were found. The left thigh was swollen, painful, with discoloration of the skin, warm on palpation. The patient was initially upset, with inappropriate social behavior.

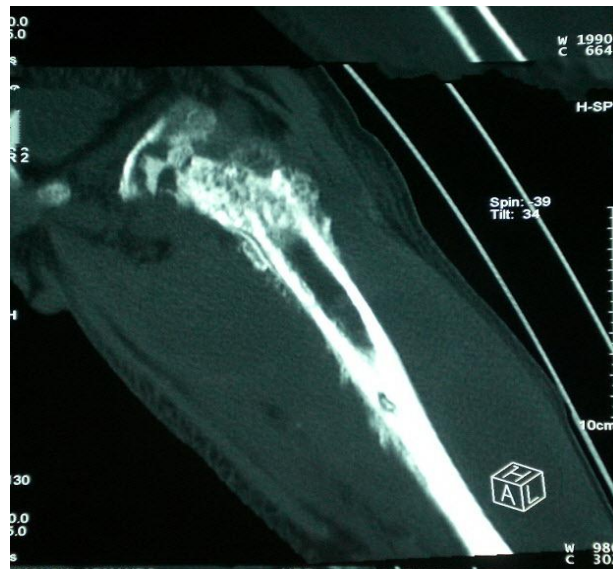
Initial laboratory investigations showed anemia (hemoglobin at 78 g/l) and normal white blood cell count per  $7,4 \times 10^9/l$ . The erythrocyte sedimentation rate was found to be 119. C-reactive protein was 36,5 mg/l. Laboratory analyzes also revealed elevated levels of D-dimer 1575 ng/ml. The results of

repeated cultures revealed no growth of pathogens. Wound swab test was positive for Methicillin-resistant *Staphylococcus aureus* (MRSA). The patient was positive for hepatitis B and C.

Plain radiographic findings and CT scan of the left thigh and femur confirmed the diagnosis of osteomyelitis, shown in Figure 1 and Figure 2. Doppler echo of the blood vessels of the left leg detected deep vein thrombosis.



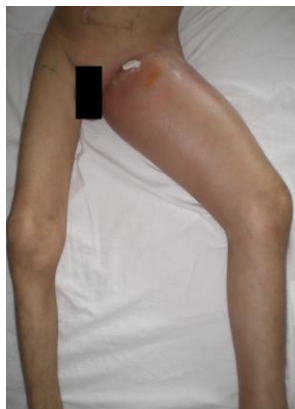**Figure 1.** The anteroposterior radiograph shows altered skeletal structure of the left proximal femur metadiaphysis with osteolytic and osteosclerotic changes, a pronounced periosteal reaction, and marginal irregularity of metaphysis.



**Figure 2.** CT scan of the left thigh and femur showed bone destruction of the left femoral head and neck with pyarthrosis. Expressed periosteal reaction with pyomyositis of deep musculature.

Extensive antibiotic treatment and anticoagulation therapy were performed. Despite the administered therapy, the patient's clinical status improved very slowly. Persistent severe pain in the left

leg, inability to move, increased local temperature, swelling and overlying skin erythema are shown in Figure 3. Left thigh circumference rapidly increased.



**Figure 3.** Swollen left thigh with increased volume and redness

Due to the severity of the disease, a team of physicians from different specialties: pediatricians and consultants from orthopedic surgery, transfusion medicine and infectious diseases were repeatedly consulted for further therapy.

The treatment was prolonged with parenteral antibiotics, generally with an aminoglycoside (amikacin) and glycopeptide antibiotic (vancomycin), later oral antibiotics (cefixime), anticoagulant therapy, incision and drainage.

Despite many examinations by an orthopedic surgeon, radical surgery was not performed. Only medical conservative treatment was advised. Subsequently, over a long period of time, inflammatory markers showed a declining trend and antibiotics were discontinued.

### **Discussion**

Osteomyelitis can affect children of any age, but is still more common in premature babies and in children whose delivery was accompanied by complications. Acute osteomyelitis in children is significantly more common in low-income countries compared to high-income countries [2].

When the diagnosis of osteomyelitis is established, according to the duration of the disease, it is classified as acute if it persists less than 2 weeks, subacute for a duration of 2 weeks to 3 months, and chronic for more than 3 months [3,4].

Osteomyelitis is most often caused by a bacterial infection. Infections of the bone structures and joints in children are primary hematogenous in origin, although can be secondary to penetrating trauma, after surgery, or by passing the infection from an adjacent site.

There are significant differences in reports about microbiological causes of bone and/or joint infections in drug addicted patients. Older studies published in the United States until 1979, generally identified *Pseudomonas aeruginosa* as the most common cause of osteomyelitis [5,6].

On the other hand, recent studies in the USA and Spain report that *Staphylococcus aureus* is the most common cause of infection [7,8].

*Staphylococcus aureus* was isolated on culture from wound swab in our patient.

Intravenous drug use is associated with accompanying complications that most often appear on the skeleton, muscles or the vascular system [9].

Hammond and Macnicol in a group of 16 children with osteomyelitis of the proximal femur, report delayed diagnosis in one patient who underwent an unnecessary appendectomy [10].

The same issue happened to our patient.

Intravenous drug abuse can lead to serious health consequences. Nakhoul et al., in group of 250 intravenous drug abusers, found the prevalence of hepatitis B and hepatitis C was 1.2% and 15.6%, respectively. Our patient was positive for hepatitis B and C [11].

### **Conclusion**

We present a case of osteomyelitis of the proximal femur associated with intravenous drug abuse in childhood. Early treatment with antibiotics, anticoagulants and possibly surgery is essential to prevent progressive bone destruction and to minimize other systemic complications. Aggressive management and participation of a multidisciplinary team of physicians consisting of a pediatrician, orthopedic surgeon, infectologist and transfusion medicine specialist is of particular importance.

### **References**

1. Peltola H, Paakkonen M. Acute Osteomyelitis in Children. *N Engl J Med* 2014;370(4):352-60.
2. Riise OR, Kirkhus E, Handeland KS, Flato B, Reiserer T, Cvancarova M et al. Childhood osteomyelitis-incidence and differentiation from other acute onset musculoskeletal features in a population-based study. *BMC Pediatr* 2008;8:45. doi: 10.1186/1471-2431-8-45.
3. Dartnell J, Ramachandran M, Katchburian M. Haematogenous acute and subacute paediatric osteomyelitis: a systematic review of the literature. *J Bone Joint Surg Br* 2012;94:584-95.
4. Gifford DB, Patzakis M, Ivler D, Swezey RL. Septic arthritis due to pseudomonas in heroin addicts. *J Bone Joint Surg Am* 1975;57:631-5.
5. Miskew D, Lorenz M, Pearson R, Pankovich A. Pseudomonas aeruginosa bone and joint infections in drug abusers. *J Bone Joint Surg Am* 1983;65:829-832.
6. Roca RP, Yoshikawa TT. Primary skeletal infections in heroin users: a clinical characterization, diagnosis and therapy. *Clin Orthop Relat Res* 1979;144:238-48.
7. Munoz-Fernandez S, Macia MA, Pantoja L, Cardenal A, Pena JM, Martin Mola E et al. Osteoarticular infection in intravenous drug abusers: influence of HIV infection and differences with non drug abusers. *Ann Rheum Dis* 1993;52:570-4.
8. Belzunegui J, Rodriguez-Arrondo F, Gonzalez C, Queiro R, Martinez de Bujo M, Intxausti JJ et al. Musculoskeletal infections in intravenous drug addicts: report of 34 cases with analysis of microbiological aspects and pathogenic mechanisms. *Clin Exp Rheumatol* 2000;18:383-6.
9. Delaney FT, Emma Stanley E, Bolster F. The needle and the damage done: musculoskeletal and vascular complications associated with injected drug use. *Insights Imaging* 2020;11(1):98. doi:10.1186/s13244-020-00903-5.
10. Hammond PJ, Macnicol MF. Osteomyelitis of the pelvis and proximal femur: diagnostic difficulties. *J Pediatr Orthop B* 2001;10(2):113-9.
11. Nakhoul M, Carine Richa C, Jreij A, Antoine Rached AA. Prevalence of hepatitis B and hepatitis C among intravenous drug abusers in the Lebanese population. *J Infect Dev Ctries* 2018;12(2.1):28S. doi: 10.3855/jidc.10076.