

A CASE OF COVID-19 PNEUMONIA IN HEMODIALYSIS PATIENT

Stojanoska Tatjana¹, Rambabova Bushljetik I², Murtezai O¹, Taleska Matovska N¹,
Dimoska Chifligaroska E¹, Caposka O¹

¹Specialized hospital of Nephrology, Departments of Nephrology, Radiology and Physical therapy - Struga, R. of North Macedonia

²University Clinic of Nephrology, Medical Faculty, Ss Cyril and Methodius University in Skopje, R. of North Macedonia

Abstract

SARS-CoV-2 (COVID-19) is an infectious disease caused by a novel corona virus that has spread rapidly, resulting in a worldwide pandemic. Even though end-stage renal disease (ESRD) patients are particularly susceptible to COVID-19 infection and can develop severe to critical clinical presentation, there are still limited studies and case reports about COVID-19 in ESRD patients.

End-stage renal disease (ESRD) is a severe medical condition with a high prevalence of co-morbid conditions including diabetes, hypertension, and cardiovascular disease.

We report case of a 72-years-old woman with ESRD on regular hemodialysis-outpatient, with history of diabetes mellitus type-2 and hypertension, which was positive to COVID-19 and developed pneumonia. She was one of our first registered cases of COVID-19 in our hospital and was successfully cured.

Our patient reported symptoms typical of COVID-19, initially, (fever, sweating, weakness, stuffy nose, dry cough and shortness of breath, although she denied contact with infected individuals), but on the day of admission her clinical picture was atypical.

She developed a severe clinical picture with the typical presentation of COVID-19 pneumonia on chest X-ray, but without leukopenia as a typical presentation of this disease in her laboratory findings.

We describe the clinical presentation of this patient, the diagnostic process, the laboratory and imaging investigations, as well as the course and outcome of treatment.

Keywords: COVID-19, Hemodialysis, Pneumonia, x-ray.

Introduction

In December 2019, a novel coronavirus was recognized as the cause of a group of pneumonia cases in Wuhan, a city in the Hubei Province of China. It quickly spread, resulting in an epidemic throughout China, followed by a worldwide pandemic with almost 2 million confirmed cases. In February 2020, the World Health Organization (WHO) named the disease COVID-19, which stands for coronavirus disease 2019. The virus that causes COVID-19 was named severe acute respiratory syndrome coronavirus 2 (SARS-CoV-2) [1].

By the end of February 2021, over 100 million infected people have been registered, and the pandemic is still going on and is currently experiencing the third wave.

Although severe COVID-19 disease can occur in otherwise healthy individuals of any age, it predominantly affects adults with advanced age or underlying medical co-morbidities [2, 3]. End-stage renal disease (ESRD) is a severe medical condition with a high prevalence of co-morbid conditions including diabetes, hypertension, and cardiovascular disease [4]. Even though ESRD patients are particularly susceptible to COVID-19 infection and can develop severe to critical disease, there are limited studies and case reports about COVID-19 in ESRD patients.

We report our experience with one of the first diagnosed cases of COVID-19 pneumonia in a maintenance hemodialysis patient in our hospital.

This report describes the clinical presentation of this disease in a hemodialysis patient, the diagnostic process, the laboratory and imaging investigations, as well as the course of treatment.

Case Presentation

A 72-year-old hemodialysis patient presented with a history of fever, sweating, weakness, stuffy nose, dry cough and shortness of breath for three days duration, which the patient noticed at home, during the non-dialysis period and because of which she did not consult a doctor, but took an antipyretic on her own initiative.

She lived alone and she denies contacting any person suspected for COVID-19. She has been on a regular hemodialysis program for the last 4 years, 3 times a week. There were no serious complications during hemodialysis, which she preformed through a permanent vascular access: AV fistula.

She had a medical history of diabetes mellitus type-2, receiving insulin and a history of hypertension with chronic antihypertensive therapy, as well as secondary anemia and obesity as a risk factor. The patient reported the symptoms on the day she was on a regular hemodialysis program, so after the dialysis session she was admitted to our hospital, at the department for patients suspected of COVID-19. Nasopharyngeal swab was taken for a PCR test and symptomatic treatment was started. On the day of admission, laboratory tests and chest X-rays of the lungs were performed. On admission, the patient was afebrile, oxygen saturation of 85% on room air, but she needed oxygen therapy by face mask with an oxygen flow of 6-7 L / min, due to shortness of breath, but without cough and other accompanying symptoms. On physical examination, she had symmetrical breathing sounds bilaterally, with coarse inspiratory crackles which were more prominent on the left side. Her cardiovascular examination showed normal heart sounds with no murmurs or added sounds. Blood pressure was 140/80mmHg. She didn't have peripheral edema. Her abdominal and neurological examinations were unremarkable.

A chest x-ray that was performed on a day of admission showed: On both sides, in the middle and basal parts of the lung parenchyma, zones of reduced lung transparency due to pronounced bronchitic and bronchiectasis changes, spotted fibrous banded shadows that are diffusely distributed. The changes are more pronounced on the left, perichilar, pericardial, and costal, a finding suspicious of an inflammatory process present. Pronounced hills, large, vascular and stagnant. F.c. sinuses free. Heart with increased cardiothoracic index [Figure 1].

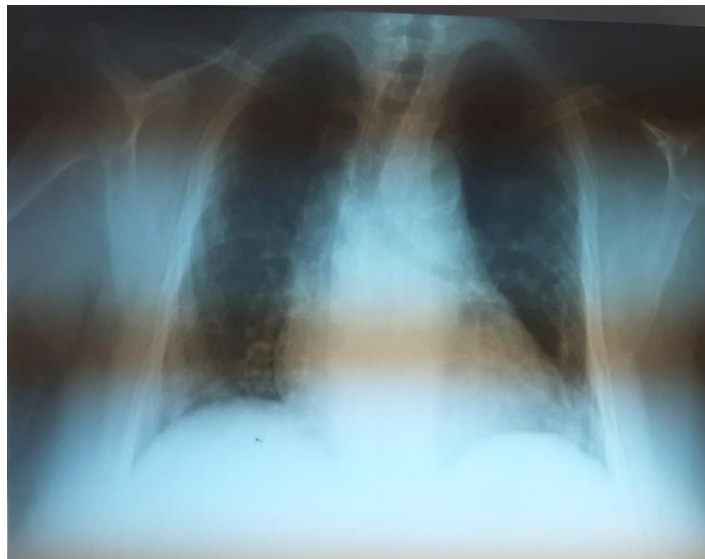

Figure 1. Chest x-ray on admission

Due to a suspicious pneumonia according to a x-ray finding a broad-spectrum cephalosporin

antibiotic therapy was initiated (with doses adjusted to patients with ESRD), corticosteroid therapy in low doses, bronchodilator therapy, anticoagulant therapy subcutaneously with low molecular weight heparin, as well as other symptomatic adjuvant therapy with vitamins and others and occasional oxygen therapy with oxygen flow 6-7L/min.

The patient was receiving regular insulin and antihypertensive therapy. Two days later, the result of the PCR test was positive, which confirmed our suspicion for a COVID-19 infection. The patient was transferred to the COVID-19-positive patient department, and she performed hemodialysis in a room that was adjusted according to COVID-19 positive patient recommendations, to limit the spreading of the disease. A more detailed survey of the patient's contacts was performed.

In the following days the patient's condition worsened with the patient having lower oxygen saturation about 67%-70% and starvation for air and the need for continuous oxygen therapy through a face mask, with an oxygen flow of 6-7 L / min. The patient was afebrile throughout the hospitalization. The auscultatory findings of the lung worsened after 14 days with the appearance of wet bronchial inspiratory crackles on both sides and more pronounced on the right, due to which a control chest X-ray was taken.

Control chest X-ray finding after 14 days showed: On both sides of the middle basal parts, in the parenchyma of the lungs, are reduced zones of reduced lung transparency, from the presence of pronounced bronchitic and bronchiectasis changes. The finding still supports the presence of bilateral pneumonia [Figure 2].

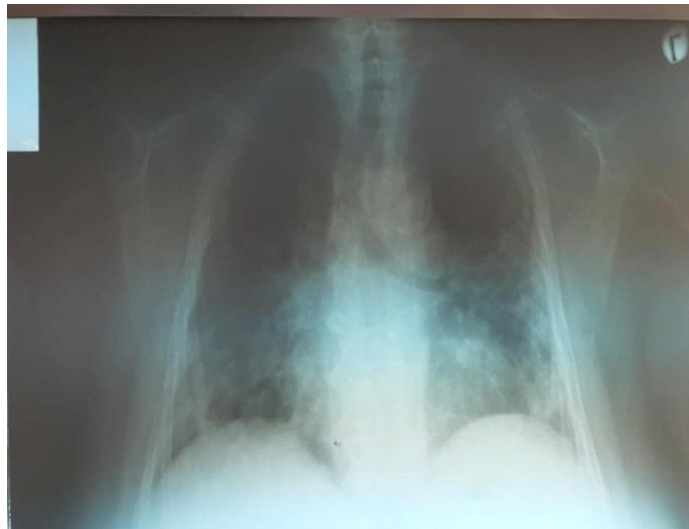


Figure 2. Chest x-ray on the day 14

After 14 days, a control PCR test was taken again, according to the protocol for monitoring and declaring cured patients. Due to a positive result the patient isolation was continued for another 7 days. The same therapy was administered for the entire time.

Over the next seven days, the patient's condition gradually but significantly improved, as did the auscultatory lung findings. In those days cephalosporin antibiotic therapy was continued and gradual discontinuation of low doses corticosteroids was performed. The therapy with low doses of corticosteroids did not significantly affect the patient's glycemic control during the hospitalization, thus the dosage of insulin therapy was not changed and the glycemic control was monitored daily. The regulation of the blood pressure was satisfactory during hospitalization with regular therapy including Angiotensin II receptor blockers (ARBs), losartan a 50 mg 2x1, and ranged between 130-90 mmHg and 160-90 mmHg. The value of D-Dimer was near the normal limits but we continued with anticoagulant therapy for few days more.

After the oxygen saturation improved and moved between 80-90% the patient no longer felt shortness of breath and only occasionally needed oxygen therapy through a face mask 4L/min.

After 21 days nasopharyngeal swab was taken for the second control PCR test was taken, and it was negative.

The patient was transferred to the department for negative patient and cephalosporin antibiotic therapy was replaced by azithromycine therapy for a further 6 consecutive days. Low-molecular-weight heparin therapy was replaced with oral acetylsalicylic acid therapy (ASA).

Due to the long hospitalization in isolation and inactivity, the patient needed physical therapy and rehabilitation which was successfully conducted in the physical therapy department of our hospital.

After 30 days of hospitalization, the patient was discharged in good health condition and was able to resume hemodialysis treatment three times a week by traveling from home to the dialysis center. Adequate diet, vitamin therapy and regular insulin and antihypertensive therapy at home were also recommended.

Table.1 Laboratory findings during hospitalization

Day	1	14	30
Hemoglobin (g/dL)	98	95	100
Leukocyte (10 ⁹ /L)	11.5	7.7	7.9
Erythrocyte(10 ¹² /L)	2.96	2.86	2.91
Thrombocyte(10 ⁹ /L)	282	222	217
ESR(>20mm/h)	78/99		56/23
BUN (g/L)	22		23.6
Creatinine (μmol/L)	665		705
Neutrophil-Lymphocyte ratio	14.4	6.2	4.5
D-dimer (ng/ml)	1883	535	438
CRP (mg/L)	>178	14.3	0.8
LDH (U/L)	320	141	
Glicemia (mmol/L)	16.2	7.8	9.7
Na (mmol/L)	132	131	133
K (mmol/L)	4.3	4.0	5.9
Ca(mmol/L)	0.99		0.95
s-Fe(μmol/L)	3.3		6.4
AST(U/L)		12	12
ALT(U/L)		16	9
Protein total(g/L)	59	60	63
Albumin(g/L)	35	33	40

A follow-up chest X-ray after a few weeks of discharge showed the following finding: In the lung parenchyma, on both sides, there are no convincing signs of fresh consolidation. Accentuated bronchovascular drawing on both sides. Hilus vascularized. F.C. sinuses free [Figure 3].

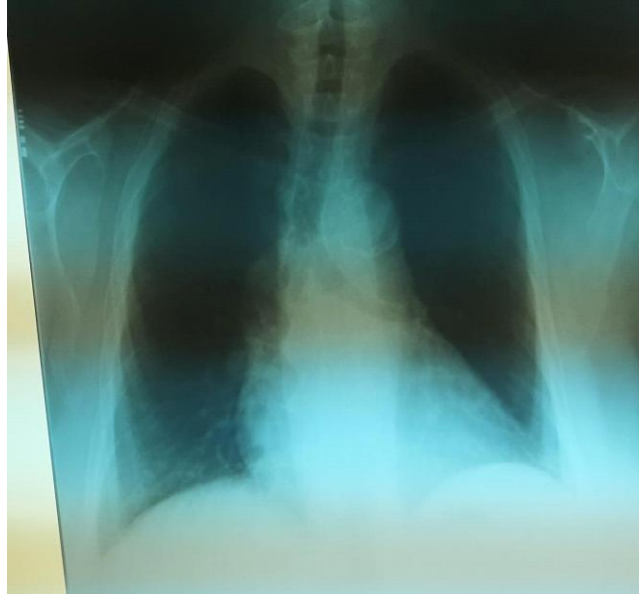

Figure 3. Chest x-ray after being discharged

Discussion

COVID-19 is an infectious disease that is mainly transmitted from person to person via respiratory droplets. COVID-19 pneumonia appears to be the most common serious manifestation of the disease. It is predominately characterized by fever, cough, dyspnea, and bilateral infiltrates on chest imaging [5, 6]. Atypical presentations of COVID-19 disease are frequent in hemodialysis patients and they are usually difficult to distinguish from other symptoms common among these patients. Wang et al. reported five cases of COVID-19 disease in hemodialysis patients in Zhongnan Hospital of Wuhan University. They found that only three out of five had a fever and that the typical triad of fever, cough, and dyspnea was not present in any of the patients reported [7].

The patient was diagnosed based on the Ministry of Health in R. of North Macedonia guidance for COVID-19, case definitions and the WHO Guidance for COVID-19. The diagnosis was confirmed by identifying SARS-CoV-2 virus nucleic acid by Reverse- Transcription Poly Chain Reaction (RT-PCR). Laboratory findings of our patient were not as typical as those described among patients with COVID-19 [6, 8]. She had no lymphopenia but had elevated inflammatory markers (ESR, CRP, D-dimer). Our patient had typical chest x-ray findings; thus CT-scan was not needed for diagnosis [9].

In our case, the patient did not have any documented fever spikes on admission or during the hospital stay. Most of the hemodialysis patients in our hospital who developed COVID-19 had atypical presentation, compared with a small number of hemodialysis patients who had a typical presentation of the disease. Almost all had a more severe clinical picture and the development of unilateral and bilateral pneumonia. More than half of these patients needed oxygen support due to reduced oxygen saturation below 80%. And almost all needed hospitalization and hospital treatment.

We had only a few cases with a milder clinical picture of COVID-19 and no complications which, during COVID-19 illness, isolated themselves at home, and were on home treatment, but continued the hemodialysis treatment on an outpatient basis, by traveling in their own vehicle to the dialysis center.

All patients underwent antibiotic therapy, corticosteroid therapy, bronchodilator therapy and anticoagulant therapy, within our treatment options, and none of the patients had the opportunity to have

antiviral or any other type of therapy administrated that was noted in certain protocols in other hospitals and other countries.

Compared with other patients with COVID-19 pneumonia and diabetes who were treated with corticosteroids during hospitalization, this patient did not need to change her insulin dose.

Also compared to other patients with COVID-19 and hypertension in this patient there were no variations in blood pressure with sudden jumps and hypertensive crises or a drop in blood pressure with collapsing conditions, as we observed in other patients during their treatment for COVID-19.

At the beginning of the pandemic, when the treatment protocol went with control PCR testing after 14 days, to be declared a cured patient, in most hemodialysis patients we found persistence of positivity after 14 days, as well as several positive cases after the second and some of them also after the third control test. We have interpreted this as a result of an inadequate immune response in these patients in general, as well as in a number of serious co-morbid conditions that could affect faster recovery in these patients.

Although in almost all hemodialysis patients that developed COVID-19 the clinical picture was severe with necessary hospitalization we did not observe higher mortality in patients on chronic hemodialysis as a result of COVID-19.

We noticed that these patients are more susceptible to this disease in which their treatment also had a large share, i.e. the need to dialyze 3 times a week for 3 to 4 hours in during which they were in contact with other hemodialysis patients and medical staff.

Due to the necessary implementation of hemodialysis treatment, the organization of work by providing appropriate isolation departments for these patients and specially adapted isolation rooms for dialysis makes the treatment of these patients much more complicated compared to the treatment of patients with COVID-19 in general population.

Conclusion

ESRD patients with COVID-19 can present atypically and the index of suspicion should be high in the setting of a pandemic to avoid exposure to healthcare staff and other hemodialysis patients.

Therefore, these patients should be tested for the slightest suspicion of COVID-19 infection, in order to be isolated in time and to prevent further spread of the disease. If possible, these patients should be screened from time to time, as well as the staff working with them.

The organization of work by providing appropriate isolation departments for these patients and specially adapted isolation rooms for dialysis makes the treatment of these patients much more complicated compared to the treatment of patients with COVID-19 in general population.

Due to the atypical presentations of COVID-19 disease in patients on hemodialysis, and because the symptoms of this disease are difficult to distinguish from other symptoms common to these patients, the diagnosis of COVID-19 is much more complicated in these patients.

COVID-19 therapy in ESRD is especially challenging due to the requirement of renal dose adjustment of various medications. Further clinical trials and observational studies are required to clearly understand the whole spectrum of clinical presentations and the optimal diagnostic and treatment methods for COVID-19 disease in hemodialysis patients.

Although the hemodialysis patients are more susceptible to this disease and almost in all of our patients who developed COVID-19, the clinical picture was serious with the necessary hospitalization; we did not see higher mortality in patients on chronic hemodialysis as a result of COVID-19, especially not in stable patients on chronic outpatient hemodialysis treatment.

Unlike the general population in hemodialysis patients, probably due to their weaker immune response, the positivity of COVID-19 may last longer, as was the case with our patient, what means that their isolation and treatment will also be longer.

This raises the question of whether these patients are longer contagious to the environment compared to previously healthy individuals who developed COVID-19.

Given everything we have as our personal experience in treating patients on a chronic

hemodialysis program and with COVID-19, we think that these patients should be in the group of priority patients for vaccination.

References

1. WHO Director-General's opening remarks at the mission briefing on COVID-19 – 16, April 2020. <https://www.who.int/dg/speeches/detail/who-director-general-s-opening-remarks-at-the-mission-briefing-on-covid-19---16-april-2020> :19.
2. Clinical course and risk factors for mortality of adult inpatients with COVID-19 in Wuhan, China: a retrospective cohort study. Zhou F, Yu T, Du R, et al. *Lancet*. 2020;395:1054–1062. [PMC free article] [PubMed] [Google Scholar]
3. Preliminary estimates of the prevalence of selected underlying health conditions among patients with Coronavirus disease 2019 — United States, February 12–March 28, 2020. Chow N, Fleming-Dutra K, Gierke R, et al. *MMWR Morb Mortal Wkly Rep*. 2020;69:382–386. [PMC free article] [PubMed] [Google Scholar]
4. System USRD. Natl Institutes Heal Natl Inst Diabetes Dig Kidney Dis., 2018 USRDS annual report: epidemiology of kidney disease in the United States; pp. 0–78. [Google Scholar]
5. Clinical characteristics of 138 hospitalized patients with 2019 novel Coronavirus-infected pneumonia in Wuhan, China. Wang D, Hu B, Hu C, et al. *JAMA*. 2020;323:1061–1069. [PMC free article] [PubMed] [Google Scholar]
6. Epidemiological and clinical characteristics of 99 cases of 2019 novel coronavirus pneumonia in Wuhan, China: a descriptive study. Chen N, Zhou M, Dong X, et al. *Lancet*. 2020;395:0–513. [PMC free article] [PubMed] [Google Scholar]
7. COVID-19 in hemodialysis patients: a report of 5 cases. Wang R, Liao C, He H, et al. *Am J Kidney Dis*. 2020; Published online ahead of print [Google Scholar]
8. Diagnosis and treatment protocol for novel Coronavirus pneumonia (Trial Version 7), April 2020; http://www.kankyokansen.org/uploads/uploads/files/jsipc/protocol_V7.pdf 2020 7:1–17. [Google Scholar]
9. ACR Recommendations for the use of chest radiography and computed tomography (CT) for suspected COVID-19 infection, April 2020; <https://www.acr.org/Advocacy-and-Economics/ACR-Position-Statements/Recommendations-for-Chest-Radiography-and-CT-for-Suspected-COVID19-Infection>. 2020