

## EXTRACTION OF ECTOPIC MAXILLAR THIRD MOLARS AFTER CONE BEAM COMPUTED TOMOGRAPHY SURGICAL PLANNING: A CASE REPORT

Brzakov Riste<sup>1</sup>, Nikolovski B<sup>2</sup>, Radojkova Nikolovska V<sup>3</sup>, Dimova C<sup>1</sup>

<sup>1</sup>Faculty of medical sciences, University Goce Delcev, Stip, North Macedonia

<sup>2</sup>University Dental Clinical Centre St. Pantelejmon, Skopje, North Macedonia

<sup>3</sup>Faculty of dentistry, Ss. Cyril and Methodius University, Skopje, North Macedonia

### Abstract

Intraoperative imaging is increasingly used by surgeons and has become an integral part of many surgical procedures. Ectopically impacted third molars in the upper jaw, become a common developmental abnormality.

Surgical planning of a case with bilaterally impacted maxillary teeth by using cone beam computed tomography is presented. The 3D model provide valuable information for improved diagnosis and treatment plan and ultimately results in more successful treatment, as in the present case.

The surgeon, knowing the precise location of the tooth and shape of roots in all projections would reduce the invasiveness of surgery. This report describes a case of impacted upper wisdom teeth without any associated pathologic condition.

**Keywords:** third molar; ectopic molar, maxillary sinus; headache; cone beam computed tomography

### Introduction

Impaction of a tooth is a situation in which an unerupted tooth is wedged against another tooth (or teeth) or otherwise located so that it cannot erupt normally. According to Peterson, an impacted tooth is one which fails to erupt within the dental arch in the expected time[1].

Ectopic tooth usually impact in an unusual position or away from their anatomic position. They can be permanent, deciduous or supernumerary. Many theories have been suggested on the aetiology of ectopic eruption such as trauma, infection, pathologic conditions, crowding and developmental anomalies [2].

The maxillary sinus, palate, mandibular condyle, coronoid process, orbit, nasal cavity or through the skin are common maxillofacial areas for the ectopic eruption. Developmental disturbances such as cleft palate, displacement of teeth by trauma or cyst, infection, genetic factors, crowding and dense bone are the possible causes of the ectopic tooth into maxillary sinus [3-6]. Caldwell- Luc procedure and the endoscopic surgical approach are common techniques for removing ectopic teeth from the sinus although latter has less morbidity [7].

Treatment decision on the impacted teeth has depended on several factors, including location of the impaction, prognosis of the intervention on the impacted tooth and adjacent teeth, surgical accessibility, impact of treatment on the final functional occlusion, and possible surgical morbidity. This decision has traditionally been based on planar 2-dimensional (2D) radiography. New imaging techniques are now available in dentistry, like cone-beam computed tomography (CBCT), which has a lower-dose, lower-cost alternative to conventional CT and is being used for localization of tooth impaction. These machines use cone-shaped radiation to gather information in the maxillofacial region, with high spatial resolution and significantly decreased radiation doses [8,9].

Knowledge of such anomalies may be helpful for the ear, nose and throat, oral and maxillofacial surgeon for the early diagnosis and treatment, hence avoiding the unnecessary hassle of the patient [10].

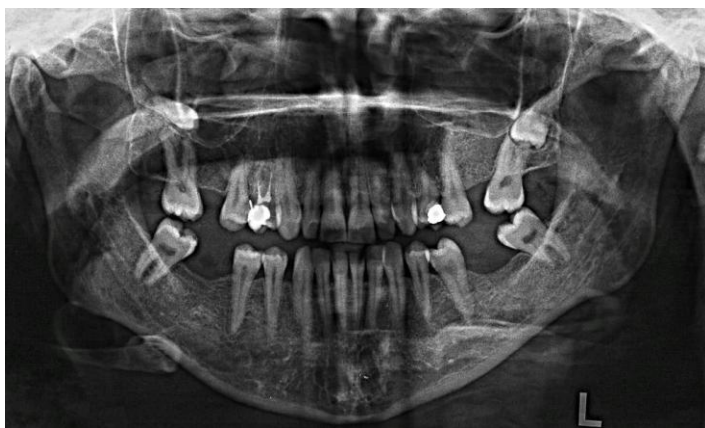In this report, the surgical planning of a case with bilaterally impacted maxillary teeth by using CBCT is presented.

A 42 years old woman was referred to the clinic with a complaint of facial pain and headache for almost a year. The past medical history was unremarkable. There was no obvious sign of disorder on both extra- and intraoral examinations. Her specialists (neurologist and ENT physician) told her that no signs of any disorders but, based on panoramic radiograph, the possible cause of pain might be the impacted maxillary teeth. There were no signs of temporomandibular joint disorders such as disc displacement with or without reduction and osteoarthritis.

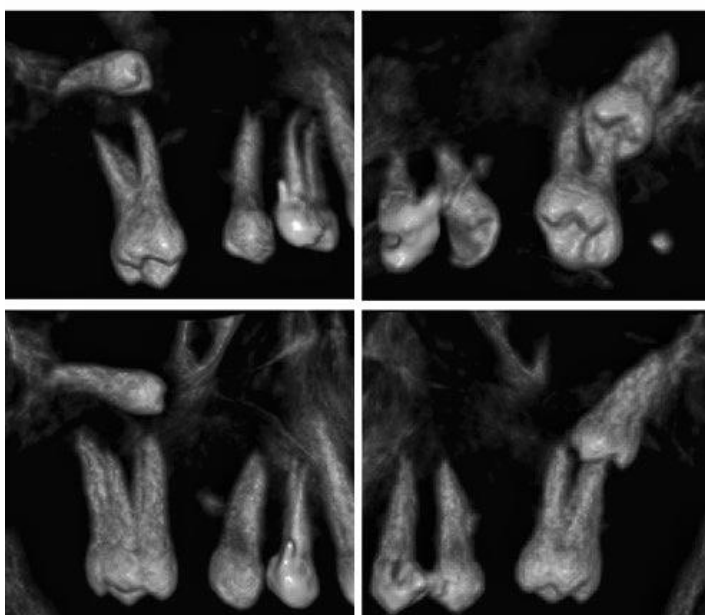
On panoramic radiograph, both third molars were impacted with a connection to the root of second molar and maxillary sinus (Fig. 1). CBCT scans were performed to evaluate the position and direction of the

impacted teeth in the maxillary sinus and related tooth. Both coronal and sagittal images showed the close proximity to the root of left second molar and right maxillary sinus.

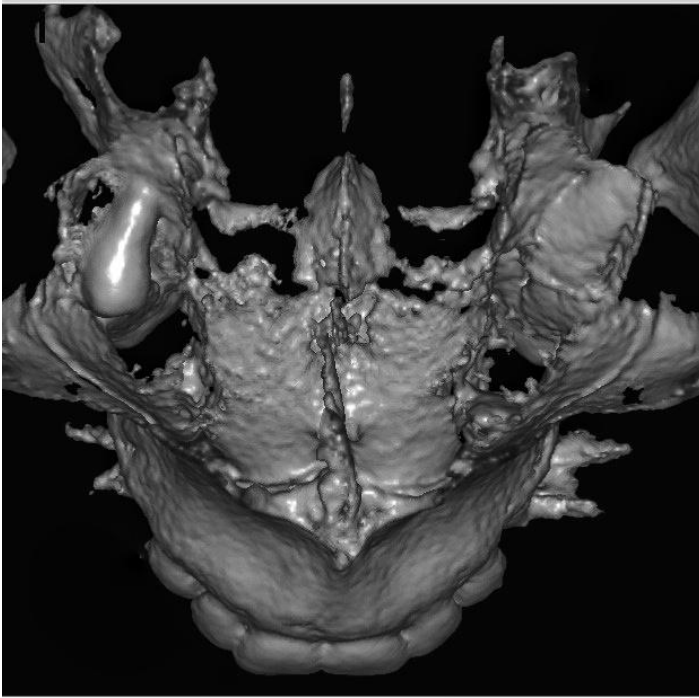
The root of left second molar without sign of resorption was placed in the middle of occlusal surface of the impacted tooth (Fig. 2). There was no dilacerations of roots of both impacted teeth. On the frontal view of 3D volumetric image, while the right tooth without bone coverage was in the maxillary sinus, the crown of the left impacted tooth was full covered with bone (Fig. 3). On sagittal views, there was no bony structure on the impacted teeth and close proximity to maxillary sinus (Fig. 4, a and b).



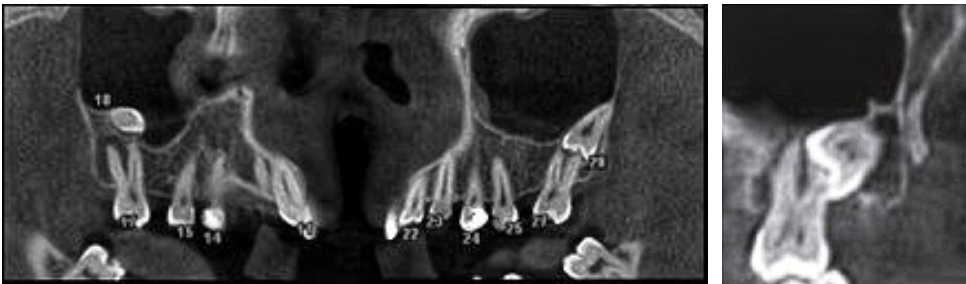**Figure 1.** Panoramic view of bilaterally impacted maxillary third molar



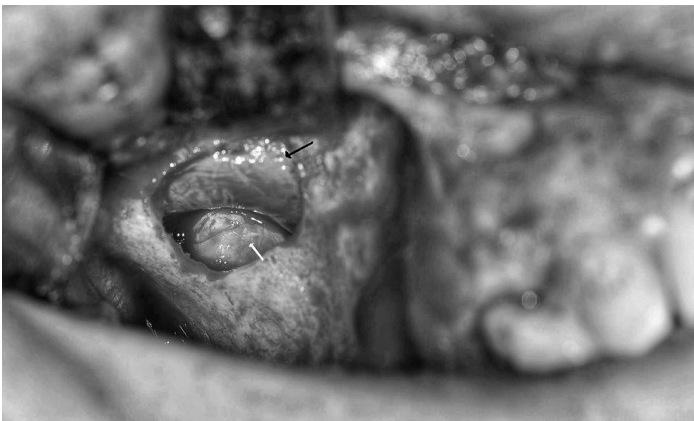**Figure 2.** 3D CBCT image shows the close proximity to the root of the left second molar and proximity to the right maxillary sinus; the root of the left second molar is placed in the middle of occlusal surface of the impacted tooth



**Figure 3.** On the frontal view of 3D volumetric image, while the right tooth, without bony coverage, was in the maxillary sinus, the crown of the left impacted tooth was fully covered with bone

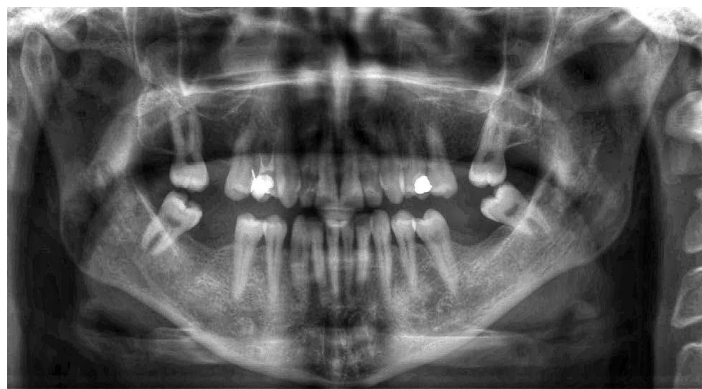


**Figure 4.** The sagittal view of the right (a) and lateral view of the left (b) impacted maxillary teeth



**Figure 5.** The impacted tooth (white arrow) was seen under the sinus mucosa (black arrow)

Under sedation, Caldwell-Luc procedure was performed for the removal of the right upper wisdom tooth, while a standard third molar surgery was made for the other. The right wisdom tooth between sinus mucosa and alveolar bone was carefully removed without mucosal perforation of the sinus (Fig. 5). Postoperative period was uneventful and no complaints at 2 years follow-up (Fig. 6).



**Figure 6.** Final panoramic view of patient

### Discussion

Although most of impacted teeth in the maxillary sinus are asymptomatic and usually found during routine clinical and radiographic examinations, facial pain associated with intermittent purulent nasal discharge and headache can be the main complaints[3].

It has been reported a case with facial asymmetry because of bilateral ectopic third molars in the maxillary sinus causing osteomeatal complex obstruction[4]. Based on the present case complaints, the impacted maxillary teeth could be one of the factors of the facial pain and headache.

CBCT is a valuable imaging technique in oral and maxillofacial surgery (OMS) that can help direct a surgeon's approach to a variety of conditions. A 3-dimensional analysis of head and neck anatomy allows practitioners to plan appropriately, operate with confidence, and assess result post-operatively. It offers 3-dimensional and multi-planar views for a more accurate diagnosis and treatment without the financial burden and radiation exposure of conventional computed tomography (CT) scans. Furthermore, CBCT overcomes certain limitations of 2-dimensional imaging, such as distortion, magnification and superimposition [11].

CBCT images are inherently more accurate than traditional x-rays, since beam projection is orthogonal; this means that the x-ray beams are approximately parallel to one another, and the object is near the sensor. This explains why there is little projection effect and no magnification. In addition, the computer software addresses the projection effect, resulting in undistorted 1:1 measurements [12].

This contrasts with traditional imaging, which always has some projection error because the anatomic regions of interest are at varying distances from the film. In this situation, the dentist must account for these imaging artefacts when reading the images. Another advantage of the CBCT scan is that the data acquired include information for the entire craniofacial region. Additional views, such as lateral cephalograms, panoramic radiographs, airway evaluations and volumetric images, are available from the original acquisition data. These images can be manipulated with imaging software to aid the dentist in diagnosis and treatment planning. The costs, efficiency, and benefits of CBCT imaging are favourable, because one imaging session can provide many views [13].

In the present case, both impacted third molar with a connection to the root of second molar and maxillary sinus were not clearly demonstrated on panoramic radiography. The best images demonstrating the bone and/or mucosa of maxillary sinus were taken on frontal view of 3D CBCT.

A common application of CBCT is in evaluation and surgical planning of impacted teeth [5,14].

The additional third dimension provided by CBCT increases the information available for the surgeon while planning exposure or removal, and may notably alter the prevalence of root resorption[15].

To take full advantage of the information provided by CBCT, it is necessary to interpret volumetric images on a 3D scale. Such a technique would enable clinicians to describe and evaluate pathologies, deformities, and impactions with greater detail and accuracy[16].

## Conclusion

In conclusion, the case presented here describes the spatial relationship of the impacted third molar to the surrounding anatomic structures using CBCT.

3D computed tomographic model provide valuable information for improved diagnosis and treatment plan and ultimately results in more successful treatment, as in present case. The surgeon, knowing the precise location of the tooth and shape of the roots in all projections would reduce the invasiveness of surgery.

## References:

1. Peterson LJ. Principles of Management of Impacted Teeth. In: Peterson LJ, Ellis E III, Hupp JR, Toker MR, editors. Contemporary Oral and Maxillofacial Surgery, 3rd ed. St. Louis: Mosby; 1998; 215-48.
2. Raghoobar GM, Boering G, Vissink A, Stegenga B. Eruption disturbances of permanent molars: a review. *J Oral Pathol Med*, 1991; 20:159-166
3. Baykul T, Dođru H, Yasan H, Cina Aksoy M. Clinical impact of ectopic teeth in the maxillary sinus. *Auris Nasus Larynx*, 2006; 33:277-281.
4. Jude R, Horowitz J, Loree T. A case report: Ectopic molars that cause osteomeatal complex obstruction. *J Am Dent Assoc*, 1995; 126:1655-1657.
5. Kim SJ. Cone beam computed tomography findings of ectopic mandibular third molar in the mandibular condyle: report of a case. *Imaging Sci Dent*, 2011; 41:135-137.
6. Bhat, Supriya, F. Ka, G. Babu and K. Saidath. "Ectopic positions of third molar-Maxilla and Mandible. *Journal of oral medicine* 1 (2015): 80-82.
7. Hasbini AS, Hadi U, Ghafari J. Endoscopic removal of an ectopic third molar obstructing the osteomeatal complex *Ear Nose Throat J*, 2001; 80:667-670.
8. Chaushu S, Chaushu G, Becker A. The role of digital volume tomography in the imaging of impacted teeth. *World J Orthod*, 2004; 5:120-132.
9. Ludlow JB, Davies-Ludlow LE, Brooks SL, Howerton WB. Dosimetry of 3 CBCT devices for oral and maxillofacial radiology: CB MercuRay, NewTom 3G and i-CAT. *Dentomaxillofac Radiol*, 2006; 35:219-226.
10. Assouline, S. L., C. Meyer, E. Weber, B. Châtelain, A. Barrabé, N. Sigaux and A. Louvrier. "How useful is intraoperative cone beam computed tomography in maxillofacial surgery? An overview of the current literature. *International journal of oral and maxillofacial surgery* (2020): n. pag.
11. Daimi, S. R. "Bilateral Ectopic Eruption of a Maxillary Third Molar Tooth from the Infratemporal Surface of the Maxilla in a Dry Human Skull. *International Journal of Applied and Basic Medical Research* 10 (2020): 131 - 133.
12. Weiss, R. and Andrew M Read-Fuller. "Cone Beam Computed Tomography in Oral and Maxillofacial Surgery: An Evidence-Based Review. *Dentistry Journal* 7 (2019): n. pag.
13. Ludlow JB, Davies-Ludlow LE, Brooks SL. Dosimetry of two extraoral direct digital imaging devices: NewTom cone beam CT and Orthophos Plus DS panoramic unit. *Dentomaxillofac Radiol*, 2003; 32:229-234.
14. Scarfe WC, Farman AG, Sukovic P. Clinical applications of cone-beam computed tomography in dental practice. *J Can Dent Assoc*, 2006; 72:75-80.
15. Alqerban A, Jacobs R, Lambrechts P, Loozen G, Willems G. Root resorption of the maxillary lateral incisor caused by impacted canine: a literature review. *Clin Oral Invest*, 2009; 13:247-255.
16. Lou L, Lagravere MO, Compton S, Major PW, Flores-Mir C. Accuracy of measurements and reliability of landmark identification with computed tomography (CT) techniques in the maxillofacial area: a systematic review. *Oral Surg Oral Med Oral Pathol Oral Radiol Endod*, 2007; 104:402-411.