JMS2025;Vol8 (2):257-262
UDK: 616.61-006.6-073.75-053.2

RADIOLOGICAL APPROACH TO NEPHROBLASTOMA IN CHILDHOOD

Advie Memeti-Tefiku[1], Kristina Dimitrijevikj[2]
[1]General Hospital Kumanovo
[2]University clinic of pulmonology and allergology, Faculty of Medicine, University Ss."Cyril and Methodius" in Skopje, North Macedonia

Abstract

Nephroblastoma (Wilms' tumor) is the most common malignant kidney tumor in children, and the b
i In this paper, we present a case of a 4-year-old child with bilateral nephroblastoma, who underwent l right-sided nephrectomy due to a dominant tumor mass and adjuvant chemotherapy according to the SIOP p protocol. After completion of treatment, significant radiological and clinical regression of lesions in the r emaining kidney was recorded. During the follow-up of several months after the end of therapy, no signs o f relapse or new progression of the disease were observed.
r The case emphasizes the importance of multimodal treatment and careful monitoring in patients a with bilateral nephroblastoma with special emphasis on the current key role that imaging plays in preserving r enal function and achieving a favorable outcome.

keywords: nephroblastoma, bilateral, nephrectomy, regression, relapses

f
o **Introduction**

r The kidneys are formed during embryonic development from some progenitor cells. It is possible fo r some of these immature cells to remain in the kidneys even after birth. If the DNA of kidney progenitor cells mutates, the cell can acquire new properties that transform it into a cancer cell. This begins to multiply u ncontrollably, causing Wilms' tumor. In most cases, this tumor affects only one of the two kidneys, but in c are cases, about 7 percent, both kidneys may be affected.
c Nephroblastoma is an undifferentiated mesodermal tumor, which contains a variable amount of e mbryonic kidney elements (blastema, epithelium, and stroma) [1].
r Nephroblastoma is more commonly known as Wilms' tumor after Dr. Max Wilms, the German s urgeon who first described it in 1899. It is the most common renal and intra-abdominal malignancy of childhood and represents a total of 6% of malignancies in children [2]. It typically occurs in childhood with i a peak incidence between 3-4 years of age.
n

a **Radiological evaluation of nephroblastoma**

p Since clinical symptoms are often nonspecific (abdominal mass, pain, hematuria), radiological p methods are primary for initial identification and characterization of the tumor. Radiological evaluation p lays a key role in the diagnosis, staging, treatment planning, and follow-up of nephroblastoma (Wilms' t umor) in children.
x Ultrasound is the first line of diagnostic imaging because of its availability, safety (no radiation), i and sensitivity for abdominal masses in children. It can differentiate nephroblastoma from cysts, h ydronephrosis, and other solid tumors. US also allows assessment of vascularity with Doppler imaging.
a Wilms' tumors are usually hyperechoic when compared to normal renal or hepatic parenchyma. t Areas of necrosis and cysts, if present, are hypoechoic. The renal vein and inferior vena cava are carefully e valuated, with evaluation including use of color Doppler, to assess vascular extension of the tumor. The r enal vein is involved in 15% of patients, and the inferior vena cava in 5% to 10%.
y Sonography is more sensitive than computed tomography (CT) in evaluating vascular tumor extension. Involved vessels are focally enlarged and filled with echogenic tumor. Fixation of tumor t hrombus to the vascular wall suggests invasion. It may be helpful to scan the patient in the upright position t o dilate the inferior vena cava. Adenopathy is carefully sought. Normal abdominal lymph nodes are rarely v isualized by sonography in children. [3,4].
0
%

o
f

c

Non-enhanced CT will show a round, well-defined solid intrarenal mass that is less dense than normal renal parenchyma. The mass disrupts the renal parenchyma and collecting system. Calcification may be seen in up to 15% of cases. Areas of fat, necrosis, hemorrhage, and cyst formation may be evident. Enhancement is inhomogeneous and always less than normal renal parenchyma.

Central non-enhancing fluid collection suggests necrosis or hemorrhage. Tumor margins are well defined due to a pseudo capsule of compressed renal parenchyma. CT is superior to sonography in detecting perirenal extension, lymphadenopathy, and contralateral tumors by 10%.

CT evaluation of the chest should be performed concurrently: 8% to 15% of patients have pulmonary metastases. Non-enhanced magnetic resonance imaging (MRI) is as good or better than CT in evaluating renal masses, perinephric extension, contralateral kidney, and hepatic metastases. [5].

MRI more readily detects intravascular extension than CT. Wilms' tumors have longer TI and T2 relaxation times than normal renal parenchyma. Necrotic and cystic regions show significantly increased signal on T2-weighted images. Hemorrhage can be defined. The mass is of reduced signal than normal renal parenchyma (FA Hofer, personal communication). MRI is less sensitive than CT in detecting pulmonary metastases.[6]

PET-CT currently has no role in the initial diagnosis of Wilms' tumors because the overall prognosis is excellent, and radiation exposure should be minimized. In patients who relapse, routine PET-CT may be beneficial because their prognosis is more guarded, and the best chance of cure is at the first relapse.

Precise placement and detection of the full extent of metastatic disease would help survival.

Staging according to SIOP (International Society of Pediatric Oncology) or NWTS/COG (Children's Oncology Group) protocols are based on surgical, pathological, and radiological findings. Radiological images are necessary for correct preoperative staging and choice of therapy.[7]

Radiological methods are also used to monitor:

- Response to chemotherapy (change in size, vascularization)
- Other lesions in the contralateral kidney (in bilateral cases)
- Relapse detection

Differential diagnosis

Radiologically, nephroblastoma should be differentiated from:

- Nephrogenic hematoma (pre-tumor lesion)
- Multilocular cystic nephroma
- Neuroblastoma (for retroperitoneal masses)
- Lymphoma

Treatment

Unilateral Wilms' tumor is treated with nephrectomy. Neoadjuvant chemotherapy is useful for reducing the size of the tumor before surgery.

In children with bilateral disease, the therapeutic approach and philosophy are very different [8,4]. Surgery to preserve the kidneys becomes paramount. Preoperative chemotherapy is vital because each kidney is ultimately staged separately. Hemi-nephrectomy, wedge resections, and nephron-sparing surgery require accurate preoperative imaging. The surgical approach in bilateral disease is aimed at sparing any normal renal parenchyma where possible.

report

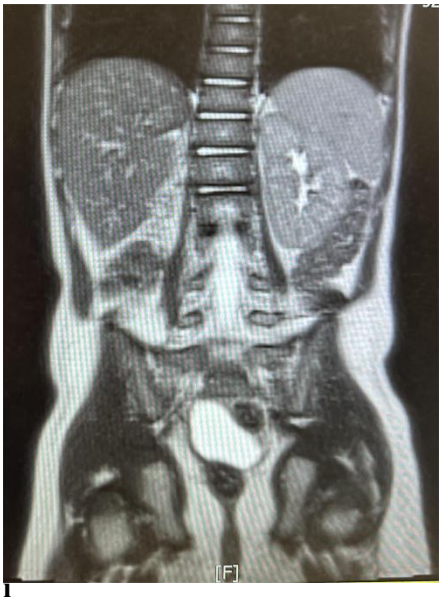

Figure

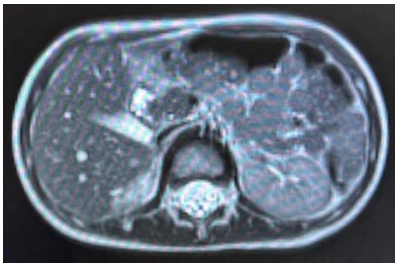

The following control ECHO examinations, laboratory and microbiological findings were normal except for high values of indirect bilirubin.

Radiological diagnostics play an essential role in the overall management of this disease – from

[
9
]
o

Laboratory tests are within reference values except for high values of LDH, which is a non-specific

n
o
t

s high (70–85%). [10,11].

References

1. Lonergan GJ, Martinez-Leon MI, Agrons GA, Montemarano H, Suarez ES. Nephrogenic rests, nephroblastomatosis, and associated lesions of the kidney. Radiographics. 1998;18(4):947–68. doi:http://dx.doi.org/10.1148/radiographics.18.4.9672980.
2. Pastore G, Znaor A, Spreafico F, Graf N, Pritchard-Jones K, Steliarova-Foucher E. Malignant renal tumours incidence and survival in European children (1978–1997): report from the Automated Childhood Cancer Information System project. Eur J Cancer. 2006;42(13):2103–14. http://www.ejcancer.com/article/S0959-8049(06)00448-5/abstract.
3. McCarville MB. Imaging neuroblastoma: what the radiologist needs to know. Cancer Imaging. 2011;11(1A): S44–7. doi:10.1102/1470-7330.2011.9008.
4. Maris JM, Hogarty MD, Bagatell R, Cohn SL. Neuroblastoma. Lancet. 2007;369:2106–20. doi:10.1016/S0140-6736(07)60983-0.
5. Khanna G, Rosen N, Anderson JR, Ehrlich PF, Dome JS, Gow KW, et al. Evaluation of diagnostic performance of CT for detection of tumour thrombus in children with Wilms tumour: a report from the Children's Oncology Group. Pediatr Blood Cancer. 2012;58(4):551–5. doi:10.1002/pbc.23222.
6. Cohen MD, Weetman RM, Provisor AJ, et al. Efficacy of magnetic resonance imaging in 139 children with tumors. Arch Surg: 121:522-529,1986.
7. Davidoff AM. Wilms tumor. Adv Pediatr. 2012;59(1):247–67.
8. Gains J, Bomanji JB, Fersht N, Sullivan T, D'Souza D, Sullivan KP. 177 Lu-DOTATATE molecular radiotherapy for childhood neuroblastoma. Nucl Med. 2011;52:1041–7. doi:10.2967/jnumed.110.085100.;
9. Lonergan GJ, Martinez-Leon MI, Agrons GA, Montemarano H, Suarez ES. Nephrogenic rests, nephroblastomatosis, and associated lesions of the kidney. Radiographics. 1998;18(4):947–68. doi:http://dx.doi.org/10.1148/radiographics.18.4.9672980.
10. Donnelly LF, Frush DP, Zheng JY, Bisset III GS. Differentiating Normal from Abnormal Inferior Thoracic Paravertebral Soft Tissues on Chest Radiograph in Children. Am J Roentgenol. 2000;175(2):477–83.;
11. McHugh K. Renal and adrenal tumors in children. Cancer Imaging. 2007;7:41–51. doi:10.1102/1470-7330.2007.0007 doi:10.1102%2F1470-7330.2007.0007.