

A rare occurrence of unilateral duplication of Wharton's duct with their intra-sublingual glandular course: a cadaveric report

Sudha Ramalingam. B.P.T., M.Sc¹, Deepa Somanath. B.H.M.S., M.Sc²,
^{1,2}Department of Anatomy, Sri Manakula Vinayagar Medical College and Hospital

Abstract

Anatomical variations regarding the salivary glands and their ducts have been observed in previous studies. But the occurrence of accessory submandibular gland duct is less common. In this study, we report a male cadaver with duplicated submandibular duct on the right side. The right upper submandibular duct (main duct) emerged from the anterior aspect of the deep part of the gland, ran its course forward, then pierced the posterior aspect of the sublingual gland and within the gland it ran forward and opened on the posterior aspect of sublingual papilla on the floor of mouth. The lower submandibular duct (accessory duct) also commenced from the anterior aspect of the deep part of the submandibular gland, ran forward just below and superficial to the upper duct and entered the anterior aspect of the sublingual gland and finally opened on the anterior aspect of sublingual papilla separately. Here, the embryological basis for the development of duplicated ducts and its clinical relevance is discussed.

Key words: accessory submandibular duct, duplicated salivary duct, sialography, sialolith, Wharton's duct

Introduction

Submandibular gland (SMG) is one of the major salivary glands located in the submandibular region of the neck. It is the first salivary gland to develop at 11.5 day of embryonic life followed by parotid and sublingual gland (SLG). The epithelium of oral cavity invaginates into the surrounding mesenchyme and shows numerous branching pattern. The terminal part of the cord remains as acini and the proximal part forms the duct [1]. The SMG duct (Wharton's duct) normally emerges from the medial surface of the superficial part after receiving many tributaries at the level of posterior border of mylohyoid muscle. It then runs within the deep part of the gland and passes upward and slightly backward for 5mm. This bend called genu which lies over the posterior border of mylohyoid muscle [2] with an angle of 102.7 degree [3]. The duct then passes forward between lingual and hypoglossal nerves on the hyoglossus muscle deep to the mylohyoid muscle. At the anterior border of hyoglossus, the duct is crossed from lateral to medial by lingual nerve and runs forward medial to the SLG and finally terminates on the sublingual papilla on the floor of mouth. Complete narrowing of the duct is defined as a kink which is observed at the hilar region, at or near the genu. Kinking may be produced by protrusion of adjacent tissue beneath the duct or because of the loosening of mylohyoid muscle [3]. The normo morpho-anatomical factors regarding SMG main duct are narrow lumen, longer and uphill course, genu and kink which act as aetiological factors for the salivary obstructive diseases like sialolithiasis, sialadenitis. Additionally if there is an accessory duct which is usually narrower and longer than the main duct, then this factor augments the possibility of developing above said conditions.

Anatomical variations can involve the number and size of the glands or their ducts. In this study we report a case with duplicated SMG duct on the right side of a male cadaver.

In a routine dissection of neck for undergraduate students of Sri Manakula Vinayagar Medical College and Hospital in the Department of Anatomy, it was noted in a male cadaver of 50 years of age, that the SMG duct on the right side was duplicated while the on the left side it was normal. The right upper SMG duct (main duct) (Fig.1,2) emerged from the anterior aspect of deep part of the gland, ran its course forward and it was crossed by lingual nerve from lateral to medial side by winding around its inferior aspect near the SLG where duct was closer to the gland than the lingual nerve. It then pierced the posterior aspect of the gland and within the gland it ran forward and opened on the posterior aspect of sublingual papilla on the floor of mouth. On its entire course it was lying

above the hypoglossal nerve. The duct was measured with vernier calliper and it measured 5.2 cm in length, breadth at its exit near the gland, at the middle part where it is crossed by lingual nerve and terminal part near the sublingual papilla were 0.3 cm, 0.2 cm, 0.1 cm respectively. The lower SMG duct (accessory duct) also commenced from the anterior aspect of deep part of the SMG, ran forward just below and superficial to the upper duct and medial to hypoglossal nerve for a distance of 5.2 cm. Further, it ascended for about 2.3 cm and entered the deeper part of the anterior aspect of the SLG and finally opened on the anterior aspect of sublingual papilla. Both the ducts were superficially covered by mylohyoid muscle.

On an attempt to trace the course of the SMG ducts, to our surprise it was found that the terminal part of the main duct (2.1cm) and the ascending part of the accessory duct (2.3 cm) were traversing the SLG before their termination. After a complete literature search, to our knowledge such a finding has not been reported so far.

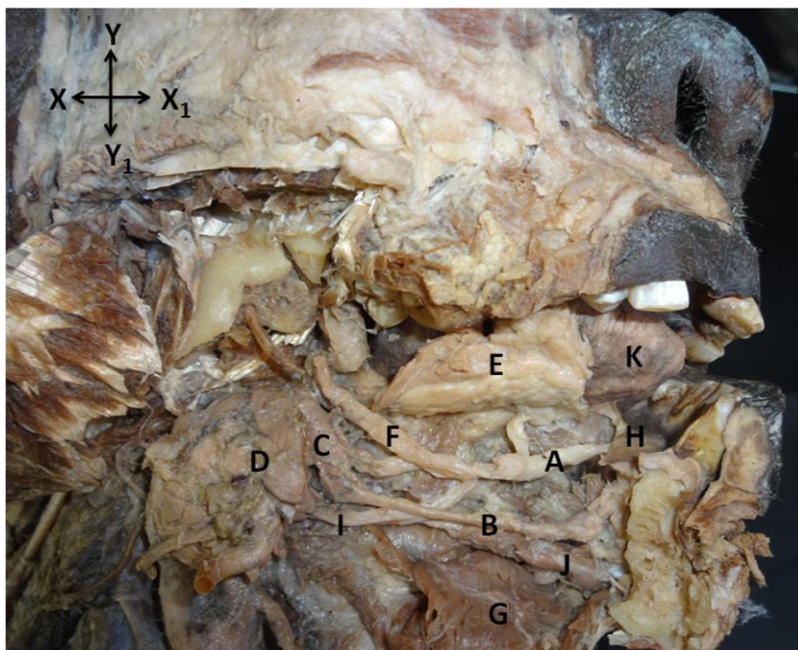


Figure (1) shows the entire course of SMG ducts after the dissection and reflection of sublingual gland on the right side (lateral view)

- A-main SMG duct
- B-accessory SMG duct
- C-deep part of SMG
- D- superficial part of SMG
- E-sublingual gland
- F-lingual nerve
- G-mylohyoid muscle
- H-sublingual papilla
- I-hypoglossal nerve
- J-geniohyoid muscle
- K-tongue
- X-Posterior
- X₁-Anterior
- Y-Superior
- Y₁-Inferior

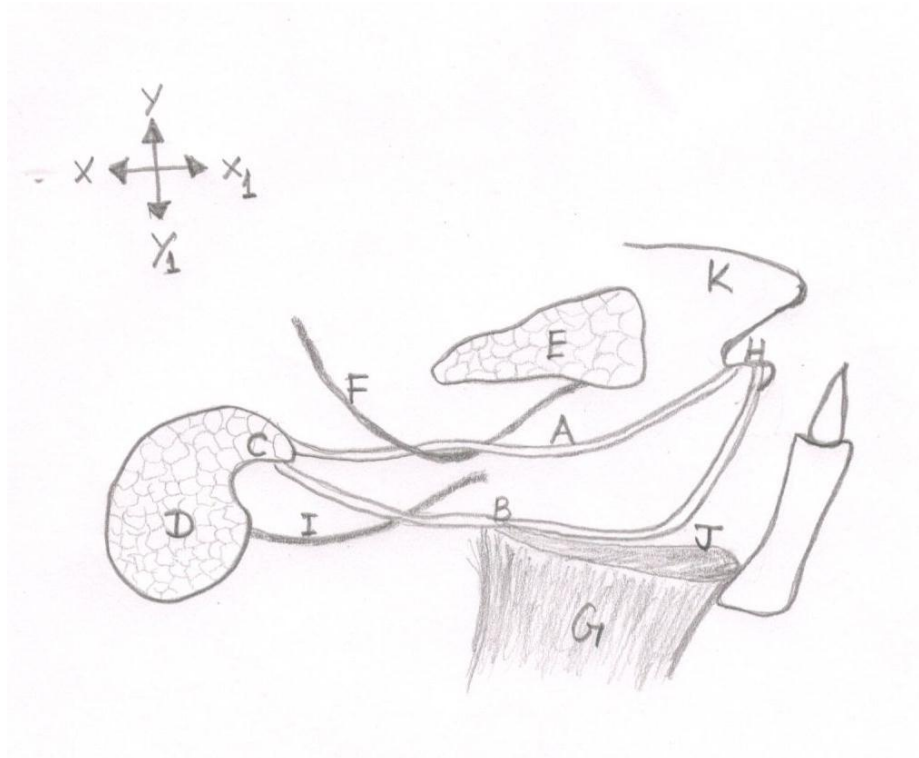


Figure (2) shows the schematic diagram of lateral view of the submandibular ducts.

- A-main SMG duct
- B-accessory SMG duct
- C-deep part of SMG
- D- superficial part of SMG
- E-sublingual gland
- F-lingual nerve
- G-mylohyoid muscle
- H-sublingual papilla
- I-hypoglossal nerve
- J-geniohyoid muscle
- K-tongue
- X-Posterior
- X₁-Anterior
- Y-Superior
- Y₁-Inferior

Discussion

The duplication of SMG duct is rarely reported. Some authors believe that the reason for duplication of duct may be attributed to the insufficient development of terminal part of the SMG duct with two premature ventral branches. This results in development of an accessory SMG duct which is found to be smaller in size accompanying the main duct to a variable length [3]. In our study, we postulate that the oral epithelium must have rolled up to form one tube with the persistence of the opening of the original epithelial placode forming another tube. Regularly, the epithelial placode for the formation of SMG appears on the floor of oral cavity. The epithelium medial to the initial epithelial placode roll upward to form the duct which in due course opens on the caruncula sublingualis. Hence, at the end of the development, the duct's opening shifts medially to the original site of placode. After the development of SMG placodes, many epithelial placodes for the SLG develop on either side of it [4]. Thus we hypothesise that the reasons for the intra-sublingual glandular course of the SMG ducts would be that the SMG duct might have opened on the original placode with the appearance of another duct medial to it, the SLG anlagen must have fused around the proximal part of the SMG ducts.

Variations in the salivary glands and its duct have been observed previously with little mention about SMG duct variation. Sometimes there can be an anatomical variation like the duct may get duplicated or triplicated. In a study by Manzur et al. there had been an incidence of SMG duct uniting with parotid duct in a male cadaver which may cause duct obstruction [5]. A study by Gadodia et al. confirmed the presence of accessory SMG and its duct by magnetic resonance imaging (MRI) [6]. Erdogan et al. conducted a MRI study where he identified the length of SMG duct as 40 to 57 mm in control group (mean 51mm) with a breadth of 1 mm [7]. In our case, the length of the main duct was found to be 5.2 cm and the maximum breadth of 0.3 cm was observed at its exit from the gland. He also reported the presence of accessory ducts in six of 40 glands in group with clinical symptoms. Billakanti identified duplication of right SMG duct which opened on the side of frenulum of tongue separately in a male cadaver [8]. Gaur et al. observed SMG with three ducts opening into the floor of mouth separately [9]. Similarly in the present cadaver, the accessory duct was opening separately on the sublingual papilla. Kuroyanagi et al. presented a case showing the SMG with accessory duct in a female during sialographic investigation [10].

Obstructive salivary gland disorders are very common which may be due to sialolithiasis, mucus plugs and strictures [11]. Sialolith is the most common salivary gland disorder. 80% of sialolith seem to occur in SMG and its duct [12] which affects male of age 30-60 years [13]. There are two hypothetical factors which play a role in the formation of sialolith. They are the content and concentration of the secretion [12] and the course and angles, narrowness of the terminal opening of the duct which cause salivary stagnation [12,14,15, 3]. Pirkl et al. documented a case of large tonsillolith in a 32 year old male patient and he revealed a fistula which was an accessory duct connecting the inferior tonsillar pole to the left SMG, measuring about 36 mm in length [16]. This finding supports the hypothesis for calculi formation. The incidence of calculi is 35% at the angulation of the duct, 30% near its terminal orifice, 20% in its medial part [14]. In the present case, the lower accessory duct was narrower and longer than the main duct. It had a vertical ascending part which ran on genioglossus muscle before its termination. This ascend can be a potential cause for stagnation to induce stone formation.

A wide knowledge about the gland and its duct is absolutely essential in clinical procedures. The conventional investigation done to find out the sialolith is sialography. During MRI sialography, the Wharton's duct may look wider than its original size as there are elastic fibres in its submucosa [3]. This has to be kept in mind during the procedure where care should be taken not to postulate more contrast medium that would result in rupture of the duct [15]. Various techniques are being used to relieve the obstruction such as sialography aided stone retrieval, sialoendoscopy, extracorporeal

shockwave lithotripsy, short tipped wire retrievable baskets [17]. Treatments for kinking are ductoplasty, balloon contouring [18]. Duplication of SMG duct may be the supporting factor for congenital cystic swelling when the orifice of the duct is very narrow. Hence in such cases, excision of duplicated duct is to be done [19, 13]. Rerouting of the Wharton's duct into the tonsillar fossa is adopted as a surgical method to control salivary drooling in case of children with neurological disorder [20]. Overlooking of accessory SMG duct might lead to the persistence of symptoms.

Accessory duct of SMG is not a common finding. Despite this, such anatomical variation should be well known by the radiologists during sialography because the duct is narrow and long. The knowledge of accessory duct enable the surgeon to reveal the potential risk factor for sialolithiasis and sialadenitis without which the case will go undiagnosed.

References

1. Tucker AS. Salivary gland development. *Seminars in Cell & Developmental Biology* 2007;18:237–244.
2. Standring S. *Grays Anatomy: The anatomical basis of clinical practice*. 40th ed. Philadelphia, Pennsylvania, USA: Churchill Livingstone; 2008. pp. 499–526.
3. Tubbs RS, Shoja MM, Loukas M. Bergman's comprehensive encyclopaedia of human anatomic variation, Hoboken, N. J : John Wiley & Sons; Inc. chapter .2016;1184-1185.
4. Som PM, Miletich I. The Embryology of the Salivary Glands: An Update. *Neurographics* 2015; 5(4):167–177.
5. Manzur-Villalobos I, Pérez-Bula L, Fang L. Anatomical variation of submandibular gland duct. *Sch. J. Dent. Sci* 2016;3(1):12-14.
6. Gadodia A, Neyaz Z, Sharma R. Magnetic resonance identification of an accessory submandibular duct and gland: an unusual variant. *J Laryngol Otol* 2007;121(9).
7. Erdogan NK, Altay C, Özenler N, Bozkurt T, Uluç E, Mete BD et al. Magnetic Resonance Sialography Findings of Submandibular Ducts Imaging. *BioMed Research International*. 2013;6.
8. Billakanti PB. Accessory Duct of the Submandibular Gland. *Sultan Qaboos Univ Med J* 2017; 17(1):e119–e120.
9. Gaur U, Choudhry RM, Anand C, Choudhry S. Submandibular gland with multiple ducts. *Surgical and Radiologic anatomy* 1994;16(4):439-40.
10. Kuroyanagi N, Kinoshita H, Machida J, Suzuki S, Yamada. Accessory Duct in the Submandibular Gland. *Asian Journal of Oral and Maxillofacial Surgery* 2007;19(2)110-112.
11. Pai A, Patil BAB, Hegde S, Sodhi A. Interventional radiology and minimally invasive techniques for the management of obstructive salivary gland disorders: A brief overview. *Journal of Medicine, Radiology, Pathology & Surgery* 2015;1:31–34.
12. Krishnappa BD. Multiple submandibular duct (Wharton's duct) calculi of unusual size and shape. *Indian J. Otolaryngol. Head Neck Surg* 2008;60:287–288.
13. Andretta M, Tregnaghi A, Prosenikliev V, Staffieri A. Current opinions in sialolithiasis diagnosis and treatment. *Acta Otorhinolaryngol Ital* 2005; 25:145-149.
14. Rzymska-Rzymska-Grala I, Stopa Z, Rzymska-Grala B, Gołębowski M, Wanyura H, Anna Zuchowska A et al. Salivary gland calculi – contemporary methods of imaging. *Pol J Radiol* 2010;75(3): 25-37.
15. Hadi Sharouny H, Omar RB. Iatrogenic Submandibular Duct Rupture Complicating Sialography: A Case Report. *Iran Red Crescent Med J* 2014;6(9): e7882.
16. Pirk I, Filipović B, Goranović T, Simunjak B. Large tonsillolith associated with the accessory duct of the ipsilateral submandibular gland: support for saliva stasis hypothesis. *Dentomaxillofac Radiol* 2015;44:20150090.
17. Buckenham T. Salivary Duct Intervention. *Seminars In Interventional Radiology* 2004; 21:3.
18. Nahlieli O, Shacham R, Yoffe B, Eliav E. Diagnosis and treatment of strictures and kinks in salivary gland ducts. *J Oral Maxillofac Surg* 2001; 59(5):48490.
19. Pal K, Abdulla AM. Congenital imperforate submandibular duct in a newborn. *Indian Journal of Pediatrics*. 2007;74.

Ramalingam S. A rare occurrence of unilateral duplication of Wharton's duct with their intra-sublingual glandular course: a cadaveric report

20. Sagar P, Handa KK, Gulati S, Kumar R. Submandibular Duct Re-routing for Drooling in Neurologically Impaired Children. *Indian J Otolaryngol Head Neck Surg* 2016; 68(1):75–79.